

## Keratin 5 Mutation in a Bulgarian Family with Dowling - Degos Disease – A Case Report and a Review of the Literature

Broshtilova V<sup>1,2\*</sup>, Todorov T<sup>3</sup>, Todorova A<sup>4</sup> and Vassileva S<sup>5</sup>

<sup>1</sup>Department of Dermatology and Venereology, Military Medical Academy, Sofia, Bulgaria

<sup>2</sup>Department of Infectious diseases, Parasitology and Dermatovenereology, Medical University, Varna, Bulgaria

<sup>3</sup>Genetic Medico-Diagnostic Laboratory Genica, Sofia, Bulgaria

<sup>4</sup>Department of Medical Chemistry and Biochemistry, Medical University, Sofia, Bulgaria

<sup>5</sup>Department of Dermatology and Venereology, Faculty of Medicine, Sofia Medical University, Sofia, Bulgaria

Volume 2 Issue 3- 2019

Received Date: 20 May 2019

Accepted Date: 03 June 2019

Published Date: 08 June 2019

### 2. Keywords

Dowling-Degos disease; Galli-Galli disease; KRT5 Mutations

### 1. Abstract

Dowling-Degos Disease (DDD) is a rare reticular pigmentary disorder with an autosomal dominant inheritance. Morbus Galli-Galli is considered to be an acantholytic variant of the disease. Mutations in keratin 5 gene (KRT5) have been found in the majority of DDD patients. Herein, the first Bulgarian pedigree with the mutation c.442\_443delAG; p.Ser148Leufs\*30 in the KRT5 gene on chromosome 12 (12q13.13), underlying the specific retiform hyper pigmentation in the clinical setting of DDD, is presented. Some clinical and histo-pathological ambiguous features are also discussed.

### 3. Introduction

The spectrum of retiform pigmentary disorders encompasses the rare Dowling-Degos Disease (DDD) with its acantholytic variant Morbus Galli-Galli (MGG), Epidermolysis Bullosa Simplex with Mottled Pigmentation (ESMP), reticulate acro pigmentation of Kitamura, dyschromatosis symmetrica hereditaria, and Darier's disease Muller et al. [1]. Interestingly, mutations in the KRT5 gene (encoding keratin 5) have been found to correspond with certain clinical dyschromic phenotypes Hanneken et al. [2]. Wide spread reticulated hyper pigmentation with skin fragility; blistering and progressive palmo-plantar hyperkeratosis has been linked to p.Pro25Leu mutation in ESMP Rugg et al. [3]. Acral reticulated hyper pigmentation, palmar pits and breaks in dermatoglyphs the typical clinical picture of Kitamura's reticulate acro pigmentation, also linked to mutation in the KRT5 gene Griffiths et al. [4]. Since 2006, the mutation c.418dupA was identified in patients with DDD, presented with reticulated hyper pigmentation mainly in flexures, perioral pitted scars, and come do-like papules on face and neck Betz et al. [5].

Herein, we present the first Bulgarian family with hereditary mottled hyper pigmentation, affecting the neck, large folds, and the

upper extremities, starting at the third decade of life, with the clinical, histology and mutational features of DDD.

### 4. Case Report

A 65-year-old Caucasian woman was referred to our Department of Dermatology with reticulate, hyperpigmented, scaly papules on the neck, lateral proximal arms, submammary and axillary folds. The patient reported that she noted the first similar skin lesions thirty years ago. Each lesion appeared as a red pruritic papule, which evolved into a hyper pigmented irregular macule. Usually, the disease recurred in summer and on sites of mechanical friction. A previous biopsy, done in another institution showed focal subbasal acantholysis that was interpreted as Darier's disease. Her past treatment regimens included topical corticosteroids and emollients. A 4-month per-oral acitretin therapy was undertaken five years ago and discontinued due to gastro-intestinal side effects.

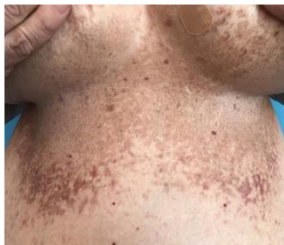On physical examination, a widespread mottled hyper pigmentation involving the neck, axillary, submammary and inguinal folds, as well as the inner aspects of both thighs, was seen (**Figure 1a, b, c**). Scaly, erythematous papules were present on the advancing

\*Corresponding Author (s): Valentina Broshtilova, Department of Dermatology and Venereology, Military Medical Academy, Sofia, Bulgaria, 3, St. Georgi Soffiskyst, 1431, Sofia, Bulgaria, Tel: +359 888 257 905, E-mail: broshtilova@mail.bg

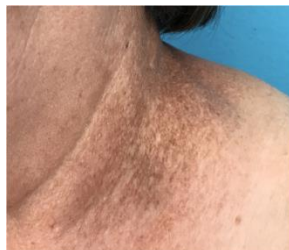Citation: Broshtilova V, Todorov T, Todorova A and Vassileva S, Keratin 5 Mutation in a Bulgarian Family with Dowling - Degos Disease – A Case Report and a Review of the Literature. Annals of Clinical and Medical Case Reports. 2019; 2(3): 1-4.

borders of the pre-existing hyperchromic macules. Neither pitted perioral acneiform scars, nor abnormalities of the hair or nails, were detected. The histology findings from an erythematous papule showed elongated epidermal rete ridges with bud-like filiform projections and suprapapillary thinning (**Figure 2**). Mixed dermal inflammatory infiltrate was seen in the superficial dermis. The absence of suprabasal acantholysis and linear clefts ruled out MGG, favoring the diagnosis of DDD.

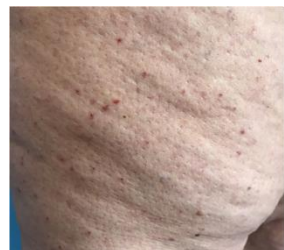The proband had no parents and siblings alive. She had three daughters-the elder born in 1974, and twins born in 1979. Since ten years the elder daughter had a few hyperpigmented macules on the neck. One of the twins, presented with localized hyperpigmented mottled patches in both axillar folds, started 3-4 years ago. Both patients denied subjective symptoms. Exacerbations occurred rarely, only in extremely hot weather and on friction. They tolerated their skin changes well and did not use any therapy. The third daughter was clinically unaffected.



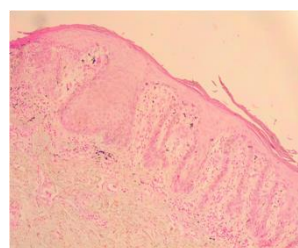
**Figure 1(a):** Mottled hyperpigmentation with peripheral scaly erythematous papules on the trunk and Inguinal folds.



**Figure 1(b):** Dyschromic macules on lateral aspect of the neck.



**Figure 1(c):** Pruritic papules on the anterior aspects of the left thigh.



**Figure 2:** Elongated epidermal rete ridges with bud-like filiform projections, suprapapillary thinning and mixed inflammatory infiltrate in the papillary dermis (x 100, PAS).

The proband and her three daughters were referred for genetic testing after written informed consent was obtained from all of them. Direct Sanger sequencing of the *KRT5* gene was performed using Big Dye Terminator Cycle Sequencing kit v.3.1 (Applied Biosystems, Foster city, CA). Primers were designed to specifically amplify the coding part of the exon and exon-intron boundaries (available upon request). The Sequencing Analysis software v.5.1.1 was used to obtain the sequencing profile.

The mutation c.442\_443delAG; p.Ser148Leufs\*30 in the *KRT5* gene on chromosome 12 (12q13.13) was identified in the clinically affected individuals, but not in the unaffected sibling. The detected genetic variant was described, based on the HGVS nomenclature guidelines ([www.hgvs.org](http://www.hgvs.org)).

## 5. Discussion

DDD is an autosomal dominant form of the retiform pigmentary disorder. It was first mentioned in 1938 by Dowling and Freudenthal [6] and later thoroughly described by Degos under the name: *dermatose reticulée des plis Degos et al Ossipowski*, [7]. Affected patients usually develop a progressive reticulate hyperpigmentation starting in the third decade of life. Tiny hyperkeratotic brown papules that mainly affect the flexures and great skin folds can also be seen. Pitted perioral acneiform scars, genital and perianal reticulated pigmented lesions are additional clinical features [8].

Originally described in 1982 by Bardach, Gebhart and Luger [9], MGG is considered to be a rare acantholytic variant of DDD. Erythematous scaly papules evolving into confluent, reticulated, hyperpigmented macules on the trunk, neck, flexor and extensor surfaces of the extremities, are characteristic features. The most important histology finding is the typical suprabasal acantholysis [10]. The clefting, itself, is considered to cause skin irritation and pruritus, seen in the affected individuals.

Remarkably, the family herein presented shows some diversity in the clinical symptoms. First, the proband had multiple red pruritic papules that better correspond to the MGG phenotype. Moreover, the distribution of the lesions is more extended than the classical DDD variants, since the lesions are not limited to the skin folds, but also involve the trunk and volar aspects of thighs. No acne-like scars are identified. The patient claimed to have itch and discomfort at the beginning of each relapse. The documentation of suprabasal clefting, which previously verified the diagnosis of Darier's disease, is also interesting. If this finding is taken into consideration, it may further contribute to the diagnosis of MGG. Of note, despite the high index of suspicion, suprabasal acantholysis was not identified in our histological sample. Therefore,

we favor the diagnosis of DDD, although many clinical features and the disputable pre-existing histology were more suggestive of MGG. Based on these observations, we dare to suggest that suprabasal acantholysis may anecdotally appear in certain DDD exacerbation episodes, probably depending on the severity of the relapse, thus confronting the mere existence of MGG.

DDD is a very rare dermatosis. The constellation of clinical and histology findings is usually sufficient to conclude the diagnosis, especially in the context of a family history and genetic background. In the last 10 years, molecular testing has been proven as the most significant and important diagnostic tool. Half of the DDD patients show *KRT5* mutations Reisenauer et al. [11]. The *KRT5* gene mutation found in our patients is the most common genetic defect. A loss of keratin 5 impairs the formation of intermediate keratin filaments, which greatly compromise the structural integrity of basal layer keratinocytes and the transfer of pigment-carrying melanosomes from melanocytes to the epidermal keratinocytes with the consequence of abnormal skin pigmentation Styers et al. [12].

Generalized DDD, disseminated on trunk and extremities, has been linked to *POGLUT1* mutation Basmanav et al. [12]; Wilson et al. [14], encoding protein O-glucosyl transferase 1. The dyschromic DDD cases with involvement of trunk, neck, and genital area were identified to have mutations in *POFUT1*, encoding a protein O-fucosyl transferase 1 Basmanav et al. [15]. Some authors tried to link the DDD clinical phenotypes with their corresponding genetic background, stating that keratin 5 affects mostly the skin folds, *POGLUT1* causes hyperpigmented macules on the trunk and extremities, while the reticulated dyschromatic macules in *POFUT1* mutation are distributed to the trunk and acral areas Hanneken et al. [16]. Our proband showed very extensive hyperchromic lesions, affecting the trunk, neck, large folds and anterior aspects of the thighs. This clinical phenotype does not correspond to the classical DDD flexural involvement, suggesting that the distribution of the lesions should not be considered specific and all patients should be put on extensive genetic testing.

## 6. Conclusion

DDD is a rare reticular hyperpigmented disorder with an autosomal dominant inheritance. MGG is considered an acantholytic variant of DDD; however, in certain individuals such suprabasal clefting seems to be transitory, depending on the severity of the relapse. Full genetic screening is needed in all patients with DDD, since no true evidence exists on the specificity of the clinico-mutational correlation.

## References

1. Muller C, Tremezaygues L, Pfoehler C, Vogt T. The spectrum of reticulate pigment disorders of the skin revisited. *Eur J Dermatol.* 2012; 22: 596-604.
2. Hanneken S, Ruetten A, Pasternack S, Eigelshoven S, El Shabrawi-Caelen L, Wenzel J et al., *Br J Dermatol.* 2010; 163: 197-200.
3. Rugg EL, McLean WH, Lane EB, Pitera R, McMillan JR, Dopping-Hepenstal PJ et al., A functional “knockout” of human keratin 14. *Genes Dev.* 1994; 8: 2563-2573.
4. Griffiths WA. Reticulate pigmentary disorders: a review. *Clin Exp Dermatol.* 1984; 9: 439-450.
5. Betz R, Planko L, Eigelshoven S, Hanneken S, Pasternack S. Loss-of-function mutations in the keratin 5 gene lead to Dowling-Degos disease. *Am J Hum Genet.* 2006; 78: 510-519.
6. Dowling GB, Freudenthal W. Acanthosis nigricans. *Br J Dermatol.* 1938; 50: 467-471.
7. Degos R, Ossipowski B. Dermatose pigmentaire réticulée des plis. *Ann Dermatol Syphiligr.* 1954; 81: 147-151.
8. Milde P, Süß R, Megahed M, Goerz G. Morbus Dowling-Degos-Kitamura. *Z Hautkr.* 1994; 69: 282-283.
9. Bardach H, Gebhart W, Luger T. Genodermatosis in a pair of brothers: Dowling-Degos, Grover, Darier, Hailey-Hailey, or Galli-Galli disease? *Hautarzt.* 1982; 33: 387-383.
10. Schmieder A, Pasternack S, Krahl D. Galli-Galli disease is an acantholytic variant of Dowling-Degos disease: additional genetic evidence in a German family. *J Am Acad Dermatol.* 2012; 66: 250-251.
11. Reisenauer A, Wordingham S, York J. Heterozygous frameshift mutation in keratin 5 in a family with Galli-Galli disease. *Br J Dermatol.* 2014; 170: 1362-1365.
12. Styers ML, Salazar G, Love R, Peden AA, Kowalczyk AP, Faundez V. The endo-lysosomal sorting machinery interacts with the intermediate filament cytoskeleton. *Mol Biol Cell.* 2004; 15: 5369-5382.
13. Basmanav F, Oprisoreanu A, Pasternack S. Mutations in *POGLUT1*, encoding protein O-glucosyltransferase 1, cause autosomal-dominant Dowling-Degos disease. *Am J Hum Genet.* 2014; 94: 135-143.
14. Wilson N, Cole C, Kroboth K, Hunter W, Mc Lean W. Mutations in *POGLUT1* in Galli-Galli/ Dowling-Degos disease. *Br J Dermatol.* 2017; 176: 270-274.

15. Basmanav F, Fritz G, Lestringant G. Pathogenicity of POFUT1 in Dowling-Degos disease: additional mutations and clinical overlap with reticulate acropigmentation of Kitamura. *J Invest Dermatol.* 2015; 135: 615-618.
16. Hanneken S, Rütten A, Eigelshoven S, Braun-Falco M, Pasternack SM, Ruzicka T et al., Galli-Galli disease a clinical and histopathological investigation using a case series of 18 patients. *Hautarzt.* 2011; 62: 842-851.