

Malignant Pheochromocytoma with Brain Abscess Induced by Nocardia Infection after Treatment with Cyclophosphamide (CVD), 5-Fluorouracil (FU) and Carboplatin (CBDCA)

Ichiro Mori¹, Kei Fujioka¹, Takahide Keda², Hiroyuki Morita², Tatsu Ishizuka^{1,*}

¹Center of General Internal Medicine and Rheumatology, Gifu Municipal Hospital, Japan

²Department of General Internal Medicine, Gifu University of Graduate School of Medicine, Japan

Volume 3 Issue 4-2020

Received Date: 07 Apr 2020

Accepted Date: 14 Apr 2020

Published Date: 20 Apr 2020

1. Abstract

A 47 years old man who had been diagnosed as malignant pheochromocytoma with metastases of lumbar spines at 21 years old. He had received partial tumor abscission, radiotherapy and ¹³¹I-MIBG treatment. He had been suffered from gait disturbance for spinal compression by the metastasis of vertebral spines at 42 years old. CVD treatment and 5-FU + CBDCA treatment had been performed for 13 cycles. After treatment with 5-FU and CBDCA, MRI imaging showed brain abscess and drainage for brain abscess had been done. *Nocardia farcinica* was identified in his brain abscess. Treatment with ST combination vanished brain abscess by MRI imaging.

2. Keywords

Malignant pheochromocytoma; *Nocardia*

3. Introduction

Pheochromocytoma is a catecholamine developing tumor originated from chromaffin tissue. Extra-adrenal tumor had been called as paraganglioma. Metastatic malignant pheochromocytoma to non-chromaffin tissues was found in 10-35% of paraganglioma. Metastasis to the bone, liver, lungs, and lymph nodes identified as non-chromaffin tissues, had been appeared, which was called as malignant pheochromocytoma [1]. CVD treatments (750 mg/m² cyclophosphamide, 1.4 mg/m² vincristine, 600 mg/m² dacarbazine) had been used as general chemotherapy [2, 4]. Serious problem should be pointed out the side effects such as myelosuppression and immunosuppression in spite of a tumor reduction.

Nocardia infection was appeared in the immunosuppression during anticancer treatments. *Nocardia* are habitually living in soil and 20-30% of pulmonary nocardiosis spreads to the central nervous system. Nocardiosis in the central nervous system had been found as the brain abscess [3]. We have reported a malignant pheochromocytoma with a brain abscess caused by nocardiosis after CVD, 5-FU and CBDCA treatments (600 mg/m² 5-FU, 180 mg/m² carboplatin).

4. Case presentation

A 47 years-old man had been diagnosed as malignant pheochromocytoma of right adrenal gland with the metastasis of lumbar

vertebrae and ribs were at 21 years old. Massive ¹³¹I-MIBG therapy was performed at Tokyo Women's Medical University two times at

30-31 years-old. However, there was no reduction of metastatic bone tumor. He had received radiation therapies in the metastatic lesions such as thoracic vertebra, cervical vertebrae, pelvis and lumbosacral spine at 35, 38, 39 and 40 years-old, respectively. He suffered from gait disturbance due to spinal cord compression, and finally anterior and posterior spinal fixation and decompression operations and also radiation therapies had been done for cervical metastatic growing tumor at 42 years-old. Moreover, he was treated with 5 mg prednisolone. At 44 years-old he became quadriplegia and bedridden. After CVD treatments (750 mg/m² cyclophosphamide, 1.4 mg/m² vincristine and 600 mg/m² dacarbazine) for 13 cycles, fortunately, the reduction of metastatic tumor was observed in the early period. Next, 5-FU and CBDCA (600 mg/m² 5-FU and 180 mg/m² carboplatin) medical treatments at 45-47 years-old for 13 cycles made reduction of metastatic tumor. At 47 years-old, his left homonymous hemianopsia had developed with anorexia for 1 month after treatment with 5-FU and CBDCA.

Physical examinations at 47 years old were as follows: His height and weight were 171.2 cm and 47.1 kg (BMI 16.1 kg/m²), respectively. Body temperature: 36.3°C, blood pressure: 96/54 mmHg, and

*Corresponding Author(s): Tatsu Ishizuka MD, PHD, Center of General Internal Medicine, Gifu Municipal Hospital, 7-1 Kashima-cho, Gifu 500-8513, Japan, E-mail: ishizuka@gifu-u.

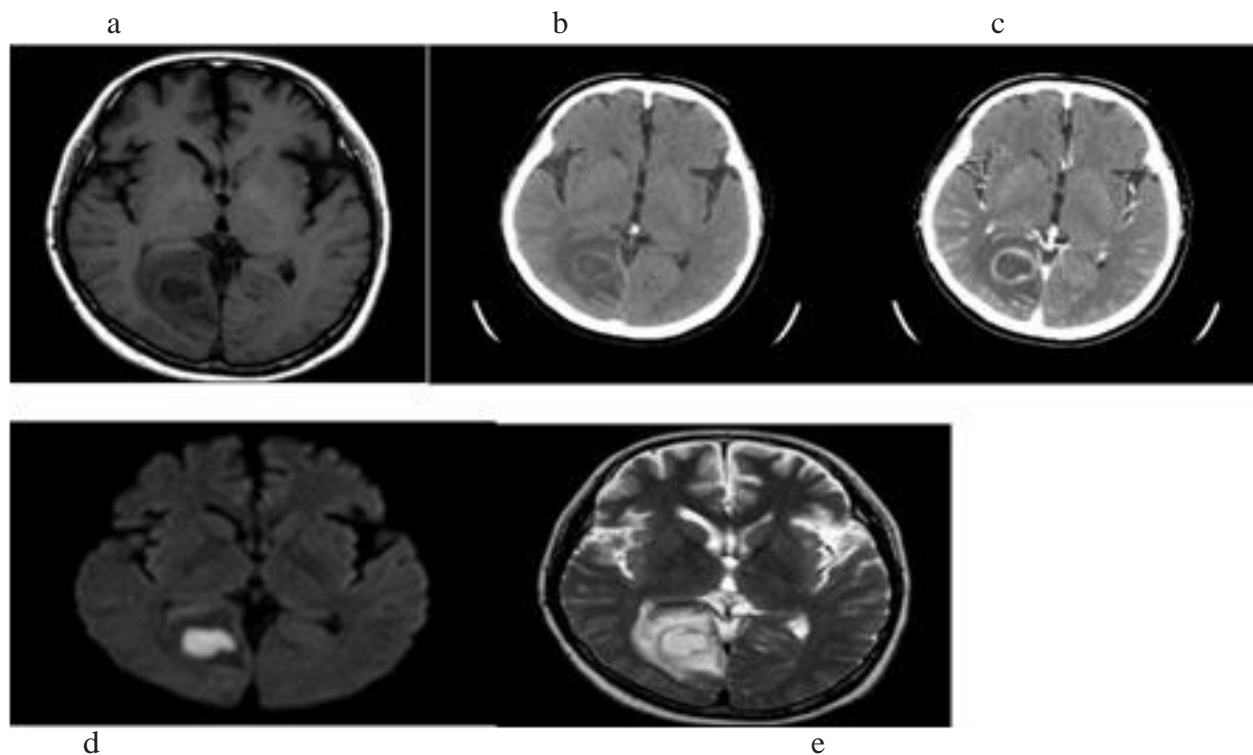
Citation: Tatsu Ishizuka, Malignant Pheochromocytoma with Brain Abscess Induced by *Nocardia* Infection

nals ofClinical andMedicalCase Reports.2020;3(4): 1-3.

pulse:72/minwerenormal.Hisconsciousnesswasclear,andthere are no dysarthria and tongue atrophy. Respiratory and circulatory systems were normal. No abdominal mass was found. However, quadriplegia,lefthemianopsia,muscleatrophiesofupperandlower extremities had been observed with no deep tendon reflexes.

As shown in Table 1, a slightly increased CRP level was found. Endocrinologicalfindingsssuchasplasmacatecholamineandthyroidhormonelevelswerenormal.Brainabscesswasdiagnosed

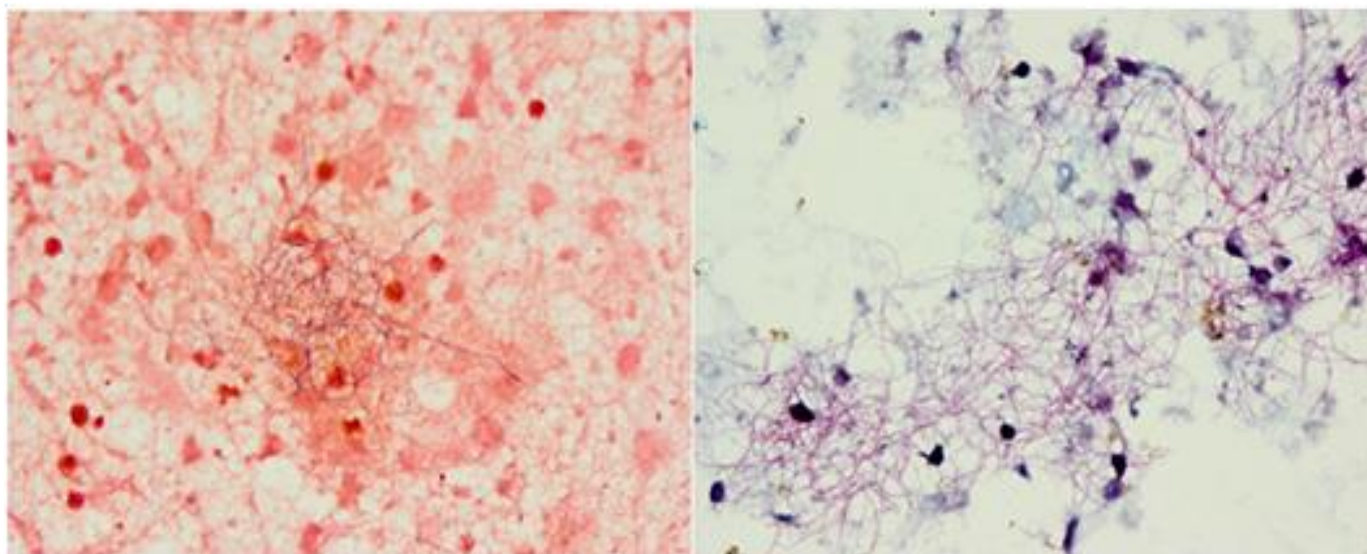
by the CT with contrast enhancement indicating space occupying lesion with ring enhancement in the occipital lobe. Draining of brainabscesshadbeenperformedatneurosurgery(Figure1).The Gram-positiverodwhichdivergedintheshapeofaspot,wasalso positive by Kinyoun staining in the draining solution. We identifiedNocardiafarcinica byculture(Figure2).TreatmentwithST (sulfamethoxazole and trimethoprim) combination had improved the left homonymous hemianopsia and brain abscess has disappeared proved by MRI images.



Figures1: Contrast Enhancement of CT scanning showed a tumor in right occipital lobe with clear round line (a and b), Brain MRI showed clear highintensity in diffusion images (c), low intensity inT1-weighted images (d) and high intensity in T2-weighted images (e) in right occipital lobe.

Gram stain

Kinyoun stain



Figures2: Histological findings indicated Nocardia farcinica by Gram and Kinyoun stainings obtained from drainage fluid in right occipital lobe.

Table1:Laboratoryfindings

Dopamine	445	µg/day	(365-962)	CRP	0.92	mg/dl	TSH	0.84	µIU/ml
Noradrena line	65.8	µg/day	(49-168)	TP	5.4	g/dl	FT3	1.83	pg/ml
Metanephrine	0.04	mg/day	(0.04-0.19)	ALB	3.4	g/dl	FT4	1.34	ng/ml
Normetanephrine	1.12	mg/day	(0.09-0.33)	CK	26	IU/l	IgG	762	mg/dl
WBC	5620	/µl		AST	44	IU/l	IgA	72	mg/dl
Neu	71.3	%		ALT	21	IU/l	IgM	46	mg/dl
Mono	8	%		LDH	187	IU/l	APTT	34.8	秒
Lymph	19.4	%		ALP	236	IU/l	PT-INR	1.33	
eos	0.9	%		γ-GT	162	IU/l	Blood cultures	-	
baso	0.4	%		UA	5.6	mg/dl	Urine cultures	-	
RBC	317万	/µl		CRE	0.29	mg/dl			
Hb	10.1	g/dl		BUN	7.8	mg/dl			
Ht	3.1	%		FBS	91	mg/dl			
PLT	13.4万	/µl		HbA1c	4.5	%			

5. Discussion

Sixty-four percent of the patients with nocardiosis are immunosuppressive. Nocardia infection was due to using glucocorticoid and anticancer agent and having a malignant tumor, transplantation, HIV infection, and diabetes mellitus [3]. In this patient, 5-FU and CBDCA medical treatments with CV catheter had caused the risk factor. Nocardia is always present in the soil in aerobic mycobacterial. The route of infection might be considered from lungs or skin, and 20% of nocardiosis appeared in brain abscess which has been reported as only solitary brain abscess. As the source of infection in this case, infected skin wound in the posterior cervical lesion after spinal fixation or CV catheters should be suggested.

The treatment for nocardiosis has been needed for ST combination therapy which might be maintained at high concentration in central nervous system for at least one year.

6. Conclusion

Here, we presented a case of malignant pheochromocytoma with improved nocardiosis of brain treated with ST combination therapy after a long treatment with 5-FU and CBDCA anti-tumor treatments. We hope to refer these clinical course and treatments for malignant pheochromocytoma and nocardiosis after strong immunosuppressive treatments.

References

1. Naruse K. The point of diagnosis and treatment in pheochromocytoma diagnosis for malignancy. Annual Review diabetes mellitus, metabolism, endocrine 2006 Chugaiigaku Co. 2006; 206-10.
2. Averbuch SD, Steakley CS, Young RC, Gelmann EP, Goldstein DS, Stul IR, et al. Malignant pheochromocytoma: effective treatment with

combination of cyclophosphamide, vincristine, and dacarbazine. Ann Intern Med. 1988; 109: 267-73.

3. Ambrosioni J, Lew D, Garbino J. Nocardiosis: Updated Clinical Review and Experience at a Tertiary Center. Infection. 2010; 38: 89-97.
4. Srimuninnimit V, Wampler GL. Case report of metastatic familial pheochromocytoma treated with cisplatin and 5-fluorouracil. Cancer Chemother Pharmacol. 1991; 28: 217-9.