

Pseudo-Abdominal Hernia: A Retrospective Study with A Review of The Literature

Sunder G^{1,*} and Vaishali S²

¹Department of Head Surgery, ESIC Medical College & Hospital Faridabad, Haryana, India

²Department of Surgery, ESIC Med Coll. & Hospital, NIT, Faridabad, India

*Corresponding author:

Sunder Goyal,
Department of Head Surgery,
ESIC Medical College & Hospital Faridabad,
Haryana, India,
Tel: 9416839094;
E-mail: goyal.sunder@yahoo.in

Received: 21 Oct 2020

Accepted: 02 Nov 2020

Published: 09 Nov 2020

Copyright:

©2020 Sunder G. This is an open access article distributed under the terms of the Creative Commons Attribution License, which permits unrestricted use, distribution, and build upon your work non-commercially.

Citation:

Sunder G, Pseudo-Abdominal Hernia: A Retrospective Study with A Review of The Literature. *Annals of Clinical and Medical Case Reports*. 2020; 5(3): 1-5.

Keywords:

Pseudo abdominal hernia; Herpes zoster; Segmental motor paresis; Herpetic neuralgia

1. Abstract

Pseudo-abdominal hernia presents as a localized compressible bulge without an actual paresis of muscles. Pseudo hernias can occur after ventral nerve root damage secondary to excision of radiculopathy, Lyme disease, poliomyelitis, syringomyelia, diabetic truncal neuropathy, polyradiculoneuropathy, prolapsed L1-L2 intervertebral disc, and rarely due to Herpes Zoster (HZ). Due to multiple causes of pseudo-abdominal hernias, there is a diagnostic dilemma. Herpetic neuralgia in a dermatomal distribution heads the rash up to 100 days, thereby further creating diagnostic puzzlement. Segmental motor paresis (pseudo-abdominal hernia) due to HZ is a rare complication. Its incidence is about 0.5% of patients and has an excellent recovery rate.

A retrospective study was done at our institution between 2012 to 2016. A total of 200 cases of HZ were recorded. Only one case of pseudohernia was found in a 60-year-old man suffering from a typical rash of herpes zoster affecting T11-T12 left dermatomes. The abdominal bulge disappeared completely after six months of observation.

2. Introduction

Herpes zoster (HZ), or shingles, is a special clinical syndrome resulting from a neurotropic virus's reactivation called the varicella-zoster virus. The initial infection causes an acute illness known as varicella, or chickenpox, which typically happens in childhood.

After the primary infection resolution, the virus can remain dormant for many years in the dorsal root ganglia's nerve cell bodies, cranial nerves, or autonomic system ganglia. The virus can persist in inactive form for years to decades without causing any symptoms. It can become reactivated at any stage due to decreased immunity and generate a clinical syndrome characterized by unilateral rash and a vesicular eruption in the affected dermatomes' cutaneous distribution. Although HZ affects the sensory nervous system primarily with characteristic painful sensory changes in a dermatomal distribution, segmental zoster paresis can also occur in the HZ syndrome [1-8]. Herpes zoster is produced by reactivating a latent varicella-zoster virus and affects about 10-20% of the general population [9]. This virus has a fondness for the posterior root ganglia as it is a neurotropic virus and mostly results in sensory, neurological complications. There is a higher incidence of reactivation among elderly and immunocompromised patients.

About 0-5% of cases develop motor complications corresponding to the involved sensory dermatomes [10]. This may result in abdominal wall weakness and can present with abdominal wall pseudohernia and rarely, along with colonic pseudo-obstruction [11]. The pseudohernia is due to the effect of increased abdominal pressure over weak musculature due to HZ. The first case of motor paresis following herpes zoster was published in 1886 by Broadbent [12]. Chernev I et al. [9] reviewed the world literature up to 2013 and reported 36 total cases in 35 articles. 37th case was reported

ed by Bashir Uzma et al. in 2014. We also add to the literature a similar case of dermatomal herpes zoster with subsequent abdominal muscle paresis and development of a pseudohernia of the left lumbar region along with colonic pseudo-obstruction.

3. Material and Method

A retrospective study was done in our institution between 2012 to 2016. A total of 200 cases of HZ were recorded. 80% of patients were in the age group of 40 to 50 years, and the male and female ratio was almost equal. 10% of patients were between 10 to 20 years, and 10% were above 50 years of age. 10 to 15% were suffering from ophthalmic HZ, and the chest area was affected in 30% of cases. The abdomen was affected by about 40% of cases. In 15% of patients, upper and lower extremities were affected. Out of 200 patients, only one patient (60-year-old man) with a typical rash of herpes zoster involving T11-T12 left dermatomes suffered from pseudohernia.

The MEDLINE, PubMed, and Cochrane databases were searched to identify reported cases of pseudohernias of the abdomen. Manual cross-referencing was performed, and relevant references of selected papers were reviewed.

4. Case Report

A 60-year-old male presented with a left lumbar abdominal wall protrusion in the surgery OPD department. He gave a history of Diabetes Mellitus. Eighteen days earlier, the patient had a painful skin rash without any prodromic symptoms. There was a history of skin vesicles and pustules' rapid eruption over the left T11-T12 dermatomes area. The patient was diagnosed with HZ and abdominal wall protrusion (Figure 1). There was no history of antiviral therapy was, and the shingles started fading. There was a history of the sudden appearance of a bulge in the left lumbar region. The bulge was painless, compressible, without any sensory deficit. It got prominent with the Valsalva maneuver.

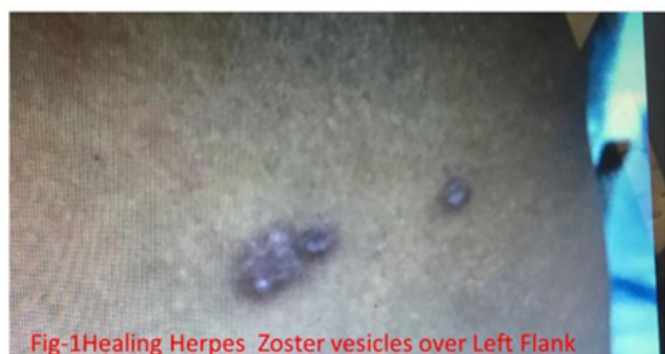

Figure 1: photo showing left flank abdominal bulge with the eruption of HZ

CECT abdomen revealed pseudohernia left flank (Figure 2). The patient also complained of constipation without any history of urinary retention. There was a neurological deficit except for a circumscribed abdominal paresis in the left flank. Electroneuromyog-

raphy and the nerve conduction was normal. On needle examination, there was denervation of the external oblique muscle. During follow-up, the patient showed improvement after two months. There was slow and gradual remission, and bulge (pseudohernia) of the left lumbar region disappeared within six months. The patient recovered from constipation also.

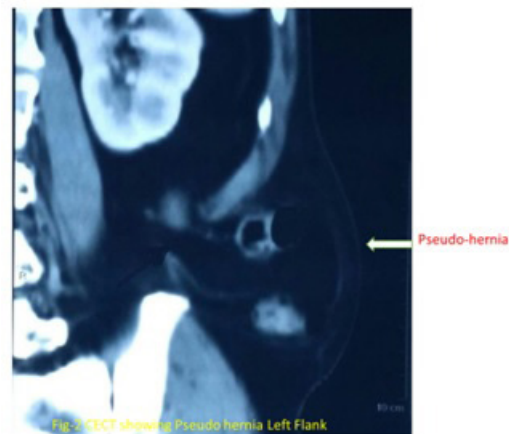


Figure 2: CECT scan showing left flank bulge

Table 1: Comparison of reported cases of postherpetic abdominal wall pseudohernia in the last 10 yrs [14]

Reported case	Age/Sex	Onset	Treatment	Remission(months)
Safadi[11]	57M	90days(d)	Observation	Five
Hanakawa et al. [15]	54 F	15 d after skin eruption	Acyclovir 1500 mg/10 days	One
Healy et.al[16]	84 M	14 days	Corset	Six
Vincent & Davis[17]	64 M	14 d	Amitriptaline 25mg/day	Three
Zuckerman & Siegel [18]	78 F	21 d	Observation	Twelve
Hindmarsh et.al[19]	64 F	14 d	Observation	One and half
Baroso [20]	72 M	20 d	Observation	Twelve
Keser [21]	82 M	30 d	Surgery	Four
Our case	60 M	18 d	Observation with abdominal corset support	Six

5. Discussion

A neurotropic virus (family of DNA viruses) is responsible for Herpes zoster. It infects one or several adjacent dorsal roots. Clinically it presents as a vesicular rash in the sensory dermatomes. Rarely, it can damage anterior horn cells simultaneously, resulting in muscular motor weakness. Motor problems can be somatic, including cranial like Ramsay--Hunt syndrome and peripheral nerves like segmental weakness of the limbs, diaphragm, and/or abdominal musculature. It can affect various visceral organs like the colonic pseudo dysfunction and urinary bladder functions also [2].

The exact incidence of segmental zoster abdominal paresis among patients with HZ is unknown so far and has been cited in different studies between 0% and 6% [1, 9]. A study done over the general population pointed out herpes zoster incidence to be 1.2-4.8 cas-

es/1000 people per year in people of all age groups. In a community older than 60 years, its incidence is about 7.2 to 11.8 cases/1000 per year. Thus the incidence of HZ increases with age and in immunocompromised individuals. The incidence of zoster paresis affecting the same segment motor weakness and skin eruptions is 1% to 5% [13].

Thomas and Howard studied 1210 patients of HZ and discovered segmental motor involvement in 61 patients (5%) and only two patients (0.2%) with abdominal wall pseudohernia [1]. In a study by Chang et al., out of 93 patients with HZ, only 11 patients (11.8%) had neurologic complications and none with abdominal wall pseudohernia [2]. In another study by Haanpää et al., out of 40 patients of HZ, only 7 (17.5%) suffered from zoster paresis, and only 2 (5%) had abdominal pseudohernia [3]. Cioni et al. studied 52 patients of thoracic HZ, and only two patients (3.8%) had clinical abdominal paresis [4]. Chernev et al. [9] We reviewed 35 articles and found only 36 cases of abdominal wall pseudohernia. The age ranged between 45 to 84 years, with a mean age of 67.5 years and a median age of 64.5 years. There were 28 males and eight females patients. In 16 patients, the left side was affected, whereas in 18 patients, the right-side was involved and, in 2 patients, the side was not mentioned. In 32 patients, the herpetic rash preceded the development of pseudohernia; in 1 case, the abdominal paresis preceded the rash, whereas, in 3 cases, there was no rash present before or after the development of abdominal paresis (zoster sine herpette). The range of onset of pseudohernia after the appearance of the characteristic rash was between 1 to 8 weeks, with a mean time of 3.5 weeks. The patients 30 patients developed the characteristic skin rash according to dermatomal distribution. Out of these 30 patients with the dermatomal distribution of characteristic skin rash, seven showed infection of different dermatomes distribution. Electrodiagnostic studies were done only in 20 cases out of 36 cases. Nineteen patients had electrophysiological changes that supported the diagnosis of paralysis and paresis of the abdominal musculature. In 2 cases, magnetic resonance imaging (MRI) was performed, and neither case demonstrated significant changes. Of the 36 cases, 23 patients had a complete recovery from their abdominal paresis symptoms. Three patients showed partial improvement at their follow-ups at 4, 6, and 7 months respectively. In 3 cases, there was no improvement at five weeks, 1.5 years, and three years follow up. Seven patients were lost during the follow-up period. The recovery time for patients with complete clinical improvement ranged from 1.5 to 12 months. HZ induced gastrointestinal (GI) problems were reported in 7 patients. Out of seven, five patients were on immunosuppressive drugs. Only one patient suffered from pseudohernia and constipation. Pseudohernia disappeared completely within six months, but constipation persisted.

The precise mechanism of abdominal muscle paresis following herpes zoster is not clear. The active inflammation spread from the

dorsal root ganglion to the anterior horn cells, and the involvement of motor nerves may be the main reason [11, 22]. Cioni et al., [23] did a pathological examination and found ganglionic lesions combined with the related sensory and motor roots and severe neuritis. This can easily clarify the clinical and electrophysiological signs. The dual innervations of the abdominal wall musculature are responsible for this rare complication. Symptoms of segmental muscle paresis frequently appear within 2 to 6 weeks after the beginning of herpes zoster, and the affected myotomes correspond to the involved dermatomes.

The diagnosis is frequently suspected by clinical evidence of HZ associated with the abdominal wall or flank bulging. Physical examination shows reduced or absent reflexes. To confirm the diagnosis, a conduction study must be done. MRI with gadolinium to define the extent of the inflammation exclude local entrapment of the spinal nerve, which is known to be a precipitating factor for HZ [4]. Neurophysiological examination, including EMG and DSPs, confirms motor and sensory loss in this unusual post-herpetic complication [24].

Our case presented with pseudo-abdominal hernia along with colonic constipation. Colonic pseudo-obstruction can start before, after, or even concurrently with skin eruptions. The Enteric nervous system may get affected due to Varicella-Zoster Virus (VZV) reactivation, which is a lethal process resulting in different gastrointestinal tract disorders, such as idiopathic gastroparesis, chronic intestinal idiopathic pseudo-obstruction, and acute colonic pseudo-obstruction [25]. Pathogenesis is not clear. Various hypotheses have been projected to explain these factors' origin, causing segmental spasm resulting in pseudo-obstruction with prominent colonic dilatation. These hypotheses are-

1. Parietal and visceral peritoneal inflammation is linked to vesicular flareup.
2. Viral infection of the extrinsic autonomic nervous system, either through anterior horn motor neurons' disease or the celiac plexus ganglion involvement.
3. Direct Varicella-Zoster Virus (VZV) injury of the ENS (Enteric Nervous System- submucosal and myenteric plexuses) and the colonic muscularis propria.
4. Hemorrhagic infarction of the abdominal sympathetic ganglia is the main mechanism of the colonic pseudo-obstruction.
5. VZV damage of the thoracolumbar or sacral lateral columns may interrupt sacral parasympathetic nerves and subsequently decrease intestinal contractility.
6. Finally, thoracic herpes zoster may prevent afferent C-fibers from facilitating gastrointestinal motility (by tachykinins), resulting in acute intestinal pseudo-obstruction [26].

Herpetic neuralgia in a dermatomal distribution occurring before the rash's appearance is well known and is noted to predate the rash by up to 100 days, thereby creating a significant diagnostic dilemma [27]. The viral spread can involve the colon and the diaphragm, urinary tract, anus, and abdominal wall, and affect their motor activity [28].

Differential diagnosis includes lumbar hernias, which can occur through the Pettit's inferior lumbar triangle or superior triangle of Grynfeltt [10]. Thoracoabdominal and lower thoracic motor radiculopathy are a rare occurrence that can clinically present abdominal wall protrusions. The differential diagnosis consists of diabetes, herpes zoster, intercostal nerve lesions, thoracic disk hernia, vertebral metastasis or trauma, and thoracic root alteration by another etiology [29].

The prognosis for patients with segmental zoster paresis is usually good. According to previous studies, improvement is seen in 55%-85% of patients with segmental herpes zoster paresis. [1, 30] In a study, Thomas and Howard [1] reported that recovery incidence is about 75%, and the other 25% of patients showed partial recovery one year from the onset of disease. In our study, 79.3% of the affected patients had complete clinical recovery in 1 year, and the remaining 20.7% showed partial recovery or no recovery. Out all, only 2 of the cases were associated with epidural steroid injections. These cases did not have a dermatomal rash. The diagnosis in these two cases was confirmed with serologically testing. The increasing age of the population and increased use of epidural steroid injection may increase HZ's complication [9].

6. Conclusion

In reality, post-herpetic pseudohernia is a changeable disease with a satisfactory prognosis. Its diagnosis is vital to avoid needless surgical interference. A high index of suspicion is important for diagnosis.

References

1. Thomas JE, Howard FM. Segmental zoster paresis: A disease profile. *Neurology*. 1972; 22: 459-466.
2. Chang CM, Woo E, Yu YL, Huang CY, Chin D. Herpes zoster and its neurological Complications. *Postgrad Med J*. 1987 Feb; 63(736): 85-89.
3. Haanpää M, Häkkinen V, Nurmikko T. Motor involvement in acute herpes zoster. *Muscle Nerve* 1997; 20: 1433-1438.
4. Cioni R, Giannini F, Passero S, C Paradiso, S Rossi, M Fimiani, et al. An electromyographic evaluation of motor Complications in thoracic herpes zoster. *Electromyogr Clin Neurophysiol*. 1994; 34(2):125-8.
5. Gardner-Thorpe C, Foster JB, Barwick DD. Unusual manifestations of herpes zoster. A clinical and electrophysiological study. *J Neurol Sci* 1976; 28:427-447.
6. Gilden DH, Kleinschmidt-DeMasters BK, LaGuardia JJ, Mahalingam R, Cohrs RJ. Neurologic complications of the reactivation of the varicella-zoster virus. *N Engl J Med*. 2000; 342: 635-645.
7. Çinar N, Şahin S, Okluoğlu T, Batum K, Karsıdag S. Is herpes zoster merely a simple Neuralgia syndrome? *Eur J Gen Med*. 2011; 8: 219-223.
8. Sachs GM. Segmental zoster paresis: An electrophysiological study. *Muscle Nerve*. 1996; 19:784-786.
9. Chernev I, Dado D. Segmental zoster abdominal paresis (zoster pseudohernia): a review of the literature. *PM R*. 2013; 5(9): 786-90.
10. Uzma Bashir*, Muhammad Irfan Anwar, Moizza Tahir. Postherpetic pseudohernia of abdominal wall: A case report. *Journal of Pakistan Association of Dermatologists*. 2014; 24 (4): 355-357.
11. Safadi BY. Postherpetic self-limited abdominal wall herniation. *Am J Surg*. 2003; 2: 148.
12. Broadbent WH. A case of the herpetic eruption in the course of branches of the brachial plexus, followed by partial paralysis in corresponding motor nerves. *Br Med J*. 1886; 2: 460.
13. Sung-Hee Kang, Ho-Kyung Song, Yeon Jang. Zoster-associated segmental paresis in a patient with cervical spinal stenosis. *J International Medical Research*. 2013; 4(3): 907-913.
14. Pedro Dantas Oliveira, Paulo Vicente dos Santos Filho, Joao Eduardo Marques Tavares de Menezes Ettinger, Isabel Cristina Dantas Oliveira. Abdominal-wall post herpetic pseudohernia. *Hernia*. 2006; 10: 364-366.
15. Hanakawa T, Hashimoto S, Kawamura J, et al. Magnetic resonance imaging in a patient with segmental zoster paresis. *Neurology*. 1997; 2: 631-632.
16. Healy C, McGreal G, Lenehan B, et al. Self-limiting abdominal wall herniation and constipation following herpes zoster infection. *QJM*. 1998; 11: 788-789.
17. Vincent KD, Davis LS. Unilateral abdominal distention following herpes zoster outbreak. *Arch Dermatol*. 1998; 9: 1168-1169.
18. Zuckermam R, Siegel T. Abdominal-wall pseudohernia secondary to herpes zoster. *Hernia*. 2001; 2: 99-100.
19. Hindmarsh A, Mehta S, Mariathas DA. An unusual presentation of lumbar hernia. *Emerg Med J*. 2002; 5: 460.
20. Barroso FA. Distension abdominal por Herpes Zoster. *Medicina (Buenos Aires)*. 2002; 62: 53-5.
21. Kesler A, Galili-Mosberg R, Gadoth N. Acquired neurogenic abdominal wall weakness simulating abdominal hernia. *Isr Med Assoc J*. 2002; 4: 262-264.
22. Oliveira P, dos Santos Filho P, de Menezes Ettinger J, Oliveira I. Abdominal-wall postherpetic pseudohernia. *Hernia*. 2006; 10: 364-6.
23. Mancuso M, Virgili M, Pizzanelli C, et al. Abdominal pseudohernia caused by herpeszoster truncal D12 radiculoneuropathy. *Arch Neurol*. 2006; 63: 1327.
24. Santiago-Pérez S, Nevado-Estévez R, Pérez-Conde MC. Herpes zoster-induced abdominal wall paresis: a neurophysiological examination in this unusual complication. *J Neurol Sci*. 2012; 312(1-2): 177-9.

25. Chen JJ, Gershon AA, Li Z, Cowles RA, Gershon. Varicella-zoster virus (VZV) infects and establishes latency in enteric 276 neurons. *J Neurovirol.* 2011; 17: 578-589.
26. Carranscosa MF, Sacines-Caviedes JR, Roman JG, Cano-Hoz M, Fernandez-Ayaa M, Caruso-Saenz E, et al. Varicella-zoster virus (VZV) Infection as a Possible Cause of Ogilvie's Syndrome in an Immunocompromised Host. *J. Clin. Microbiol.* 2014.
27. Herath P, Gunawardana SA. Acute colonic pseudo-obstruction associated with varicella-zoster infection and acyclovir therapy. *Ceylon Med J.* 1997; 42: 36-37.
28. Maeda K, Furukawa K, Sanada M, Kawai H, Yasuda H. Constipation and segmental abdominal paresis followed by herpes zoster. *Intern Med.* 2007; 46: 1487-1488.
29. Facundo Burgos Ruiz Junior, Jullyanna Sabrynsna, Morais Shinosaki Wilson Marques Junior, Marcelo Simão Ferreira. Abdominal wall protrusion following herpes zoster. *Revista da Sociedade Brasileira de Medicina Tropical.* 2007; 40(2): 234-235.
30. Tashiro S, Akaboshi K, Kobayashi Y, Mori T, Nagata M, Lui M. Herpes zoster-induced trunk muscle paresis presenting with abdominal wall pseudohernia, scoliosis and gait disturbances and its rehabilitation: A case report. *Arch Phys Med rehab.* 2010; 91: 321-325.