

## Condyloma Acuminata in an Infant: Case Report in a Resource Limited Setting

Julius ME<sup>1\*</sup>, Defang EA<sup>2</sup>, Dorothy N<sup>3</sup>, Yong OK<sup>3</sup> and Forbinake NA<sup>4\*</sup>

<sup>1</sup>HIV Free Project, Cameroon Baptist Convention Health Services, Cameroon

<sup>2</sup>Obstetrician/ Gynaecologist Kumba District Hospital, Cameroon

<sup>3</sup>Kumba Baptist Health Center, Cameroon Baptist Convention Health Services, Cameroon

<sup>4</sup>Hebrew University of Jerusalem Braun School of Public Health and Community Medicine, Cameroon

### \*Corresponding author:

Mekolle Enongene Julius  
HIV Free Project, Cameroon Baptist  
Convention Health Services, Cameroon,  
Email: mekojulio@yahoo.com

Received: 25 Nov 2020

Accepted: 11 Dec 2020

Published: 15 Dec 2020

### Copyright:

©2020 Julius ME et al., This is an open access article distributed under the terms of the Creative Commons Attribution License, which permits unrestricted use, distribution, and build upon your work non-commercially.

### Author's contributions:

MEJ, ND, EAD, NAF and OKY. These authors have contributed equally to this article.

### Citation:

Julius ME. Condyloma Acuminata in an Infant: Case Report in a Resource Limited Setting. Annals of Clinical and Medical Case Reports. 2020; V5(5): 1-4.

## 1. Abstract

**1.1. Background:** Condyloma acuminata are soft, skin colored, fleshy warts that are caused by the Human Papilloma Virus (HPV), typically HPV 6 and 11 genotypes.

The disease is highly contagious, can appear singly, confluent, multiple, small or large. The incubation period may be from 1-6 months. Although anogenital warts are considered to be sexually transmitted in adults, this may not be the case for children.

Genital warts in children may result from several modes of transmission: from the maternal genital tract autoinoculation, from finger warts and nonsexual transmission from members/careers. Generally, diagnosis of anogenital warts is usually made on physical examination. Surgical treatment options include cryotherapy, laser vaporisation, electrocautery and excision. Nonsurgical approaches in children include the use of podophyllotoxin and imiquimod.

**1.2. Case Presentation:** The presented case is a 12-month-old girl who was brought in for consultation by her mother with a 6 month history of papillomatosis changes in the anogenital area. The child was born by vaginal delivery after full term normal

pregnancy. No maternal medical history of genital warts during her pregnancy. Physical examination of the child was normal except for the presence of multiple light purple skin-colored, confluent verrucous eruption affecting the vulva and perianal region

**1.3. Conclusion:** We conclude from this case that condyloma acuminata are not only transmitted sexually but through nonsexual ways as well, such is this case, from the infected mother to the infant. We also report safe and effective treatment of anogenital warts in a child with regular and carefully applied 25% Podophyllotoxin solution.

## 2. Introduction

Anogenital Warts (AGW) otherwise known as *Condyloma acuminata* are caused by infection with the human papilloma virus (HPV) [2].

The incidence of AGW in children is suspected to be on the rise in recent decades based on the increase in adult HPV infections. Though largely unknown, it may take from one to six months [1, 2].

Most data suggest that AGWs among preadolescent children result

from non-sexual transmission acquired either perinatally or postnatally [3]. Vertical transmission of HPVs has been reported to be responsible for at least 20% of AGWs in children [4], and occurs by contamination of the newborn descending through the birth canal, or virulascent through the membranes.

Several studies have demonstrated that HPV can be acquired in the neonatal period, persisting in some infants for up to 26 months [7]. However, in addition to sexual abuse, postnatal infections can be acquired through heteroinoculation or autoinoculation from non-genital mucocutaneous HPV sources and fomite transmission [6].

AGW is diagnosed primarily by clinical appearance. The warts start as a small, flesh-colored papule in the perianal area in males or females and subsequently grow

on the hymen, in the vestibule or vulvar areas, or around the urethra in females or less commonly on the penile shaft in males. Over a period of months or sometimes very rapidly, these lesions develop into clusters of skin-colored flat warts or somewhat pedunculated larger cauliflower or berrylike keratinized masses, similar to skin warts [8].

Surgical treatment options include cryotherapy, laser vaporisation, electrocautery, and excision. These methods are painful, often requiring general anesthesia with recurrences being common. Non-surgical approaches in children include the use of podophyllotoxin and imiquimod. Although some studies demonstrate their safety and efficacy, these drugs are not approved for use in children under 12 years of age [1, 9]. We report on a 12-month-girl with extensive anogenital warts who was successfully treated with topical 25% Podophyllin solution.

### 3. Case Report

We present a 12-month-old female patient who was brought in for consultation by her mother with a 6 month history of papillomatosis changes in the anogenital area. The child was born by vaginal delivery after full term normal pregnancy. No maternal medical history of genital warts during her pregnancy. She tested negative for Syphilis at pregnancy.

Physical examination of the child was normal except for the presence of multiple light purple skin-colored, confluent verrucous eruption affecting the vulva and perianal region (Figure 1-5). Gynecological examination showed no abnormalities. The hymen was intact, and there was no evidence of ulcerations or other signs of trauma to the vaginal or anal orifices. Biopsy of the lesion was not performed. The girl was treated with 25% Podophyllotoxin solution, carefully applied at the hospital to the lesions once a week and at every visit, there was evident reduction in the number and size of warts. Treatment was continued for a total of 6 weeks, during which time the lesions cleared almost completely (see figures).

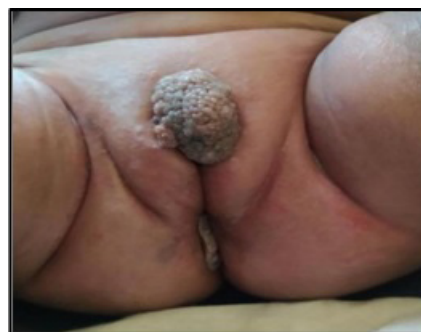

Figure 1: AGW in 12 month old at D0

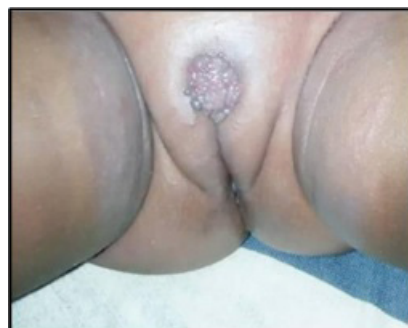

Figure 2: Week 1 Sept 27

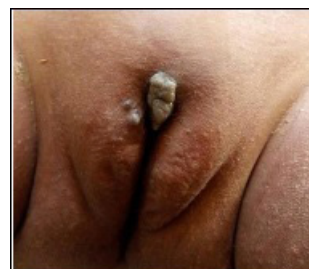

Figure 3: Week 3 Oct 4

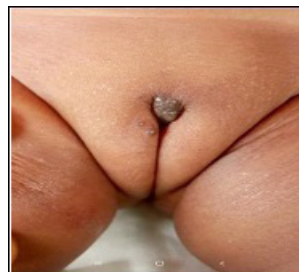

Figure 4: week 4, Oct 14

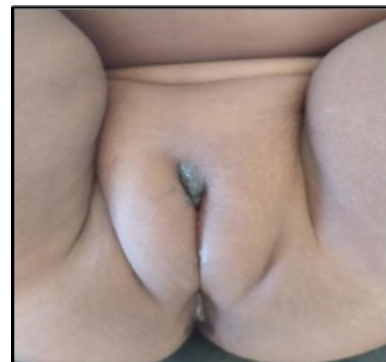


Figure 5: week 5, Oct 24

#### 4. Discussion

*Condylomata acuminata* are anogenital warts caused by the human papilloma virus (HPV). There are over 200 genotypes of Human Papilloma Viruses (HPV), 30 - 40 of which specifically affect the genital tract [10]. Genital types of HPV are divided into high or low risk according to the association with genital tract cancers. Low-risk HPV types include Types 6, 11, 42-44, and usually cause benign anogenital warts, while high-risk HPV types include Types 16, 18, 31, 33-35, 39, 45, 51, 52, 56, 58, 59, 66, 68 and 70, and cause mostly anogenital cancers, primarily cervical cancer. Low risk HPV 6 and 11 genotypes are the primary causes of condylomata acuminata [10].

Generally, the high risk population for HPV infection are sexually active young people under the age of 26, especially sexually active adolescents. Infections in paediatric population believed to be vertically transmitted from a virally infected genital tract or through caretakers with hand warts [7].

Pregnant women infected with genital warts have been shown to transmit the virus to their newborns [12], supporting the aetiology of AGW in children under 3 years.

However, sexual abuse has been linked to AGW in children and must always be ruled out through social history and physical examination for signs of abuse [13, 14]. In our case, there was no evidence of sexual abuse on clinical examination.

Diagnosis of anogenital warts is usually made on physical examination. HPV cannot be cultured. Thus, all of the HPV diagnostic methods used to date rely on viral DNA detection. Molecular biology methods, such as polymerase chain reaction (PCR) and hybrid capture, can detect genomic HPV sequences in different lesions. At present, DNA detection is an established tool for the diagnosis and monitoring of HPV-related diseases. However, there is still a need for a reference method [15]. In the absence of a sophisticated relatively costly means of diagnosis, we made the diagnosis on a clinical basis.

Treatments can be divided into nonsurgical and surgical. However, there are no FDA approved treatments for AGWs in children 12 years of age and younger. No approach has been shown to be universally successful, and recurrence is common after any form of treatment. Some children may require combination of therapies. Because recurrence is common [16].

Surgical methods involve the non-specific elimination of infected tissue, including cryotherapy, CO<sub>2</sub> laser therapy, pulsed light therapy, electrocoagulation, and surgical excision. These procedures often require local or general anesthesia [17].

Podophyllotoxin has also been reported to be effective and safe in children with genital warts [18]. Podophyllin (15%) has been reported in Iraq to be a safe alternative without any side effect or complications [19].

Podophyllin resin is an antimetabolic and caustic agent with antiviral activity. The possible mechanism of action is that it arrests cellular mitosis in metaphase, accomplished by reverse binding to tubulin which is the protein subunit of the spindle microtubules at a site that is the same of overlaps with the colchicines binding site thereby preventing polymerization of tubulin into microtubules. Therefore, it disturbs the cellular cytoskeleton; it blocks oxidation enzymes in tricarboxylic acid cycle, and interferes with nutrition of cells; it inhibits axonal transport, protein, RNA, and DNA synthesis and also inhibits mitochondrial activity and reduction of cytochrome oxidase activity. Side effects include local erythema, tenderness, burning, erosions, and edema. If podophyllin is used in an extensive area or injected or ingested, central nervous system toxicity and respiratory depression may result [16]. Bargman has reviewed the whole subject of systemic toxicity to podophyllin including its reported teratogenicity. He concluded that the dangers of podophyllin toxicity have been overplayed, and that it is an extremely safe drug when used properly [16, 20].

In our practice, Podophyllin solution 25%, 0.5 -1ml was carefully applied in the hospital and washed after an hour. The drug was used once a week for a period of 6 weeks.

#### 5. Conclusion

Podophyllin (25%) in tincture benzoin is an effective therapy for AGWs in infants and no adverse effects were noted.

#### References

1. Sinclair KA, Woods CR, Sinal SH. Venereal warts in children. *Pediatr Rev* 2011;32:115-21.
2. Turing S: Human papillomavirus infections: Epidemiology, pathogenesis and host immune response. *J Am Acad Dermatology* 2000, 43(S):18-26
3. Syrjänen, S. (2003) HPV Infections in Children. Invited Review. *Papillomavirus Report*, 14, 93-110. <http://dx.doi.org/10.1179/095741903235001425>
4. Syrjänen, S. and Puranen, M. (2000) HPV Infections in Children: The Potential Role of Maternal Transmission. *Critical Reviews in Oral Biology Medicine*, 11, 259-274. <http://dx.doi.org/10.1177/10454411000110020801>
5. Tseng, C.J., Lin, C.Y., Wang, R.L., Chen, L.J., Chang, Y.L., Hsieh, T.T. and Pao, C.C. (1992) Possible Transplacental Transmission of Human Papillomaviruses. *American Journal of Obstetrics & Gynecology*, 166, 35-40. [http://dx.doi.org/10.1016/0002-9378\(92\)91825-U](http://dx.doi.org/10.1016/0002-9378(92)91825-U)
6. Sinclair KA, Woods CR, Kirse DJ, Sinal SH. Anogenital and respiratory tract human papillomavirus infections among children: age, gender and potential transmission through sexual abuse. *Pediatrics* 2005;116:815-25.
7. LaCour DE, Trimble C. Human papillomavirus in infants: transmission, prevalence and persistence. *J Pediatr Adolesc Gynecol* 2012;25:93-7.

8. Kelly A. Sinclair, Charles R. Woods and Sara H. Sinal Venereal Warts in Children. *Pediatr. Rev.* 2011;32;115-121 DOI: 10.1542/pir.32-3-115
9. Thornsberry L, English JC 3rd. Evidence-based treatment and prevention of external genital warts in female pediatric and adolescent patients. *J Pediatr Adolesc Gynecol* 2012;25:150-4.
10. Garland, S. (2002) Human Papillomavirus Update with a Particular Focus on Cervical Disease. *Pathology*, 34, 213-224. <http://dx.doi.org/10.1080/00313020212469>
11. Shelton TB, Jerkins GR, Noe HN: Condylomata acuminata in the pediatric patient. *J Urol* 1986, 135(3):9-548
12. Silverberg N. Human papillomavirus infections in children. *Curr Opin Pediatr* 2004;16:402-9.
13. Woods CR. Sexually transmitted diseases in prepubertal children: mechanisms of transmission, evaluation of sexually abused children and exclusion of chronic perinatal viral infection. *Semin Pediatr Infect Dis* 2005;16:317-25
14. Stefanaki C, Barkas G, Valari M, Bethimoutis G, Nicolaidou E, Vossynioti V, et al. Condylomata acuminata in children. *Pediatr Infect Dis J.* 2012;31:422-4.
15. Ecdc.europa.eu [Internet]. European Centre for Disease Prevention and Control. Guidance for the Introduction of HPV Vaccines in EU Countries. Stockholm, January 2008. [updated January 2008]. [cited 2016 May 04].
16. Sharquie, K.E., Noaimi, A.A. and Almallah, M.N. (2014) Genital Warts in Infants and Children. *Journal of Cosmetics, Dermatological Sciences and Applications*, 4, 259-267. <http://dx.doi.org/10.4236/jcdsa.2014.44035>
17. Culton DA, Morrell DS, Burkhart CN. The Management of Condyloma Acuminata in the Pediatric Population. *Pediatr Ann.* 2009;38:368-72
18. Moresi, J.M., Herbert, C.R. and Cohen, B.A. (2001) Treatment of Anogenital Warts in Children with Topical 0.05% Podophlox Gel and Imiquimod Cream.
19. *Pediatric Dermatology*, 18, 448-450. <http://dx.doi.org/10.1046/j.1525-1470.2001.1980a.x>
20. Sharquie, K.E., Al-Waiz, M.M. and Al-Nuaimy, A.A. (2005) Condylomata Acuminata in Infants and Young Children. Topical Podophyllin an Effective Therapy. *Saudi Medical Journal*, 26, 502-503
21. Bargman, H. (1988) Is Podophyllin a Safe Drug to Use and Can It Be Used in Pregnancy? *JAMA Dermatology*, 124, 1718-1729. <http://dx.doi.org/10.1001/archderm.1988.01670110074020>