

## Reduce the Burden of Polypectomy with Predictable Juvenile Polyp

Kim KY<sup>1</sup> and Kim JS<sup>2\*</sup>

<sup>1</sup>Department of Pediatrics, Eunpyeong St. Mary's Hospital, College of Medicine, The Catholic University of Korea, Seoul, Republic of Korea

<sup>2</sup>Division of Gastroenterology, Department of Internal Medicine, Eunpyeong St. Mary's Hospital, College of Medicine, The Catholic University of Korea, Seoul, Republic of Korea

### \*Corresponding author:

Jin Su Kim,  
Division of Gastroenterology, Department of Internal  
Medicine, Eunpyeong St. Mary's Hospital, College  
of Medicine, The Catholic University of Korea,  
1021 Tongil-ro, Eunpyeong-gu, Seoul 03312, Korea,  
Tel: +82-2-2030-4314,  
Fax: +82-2-2030-2536,  
E-mail: jinsu23@naver.com

Received: 26 Feb 2021

Accepted: 10 Mar 2021

Published: 12 Mar 2021

### Copyright:

©2021 Kim JS et al., This is an open access article distributed under the terms of the Creative Commons Attribution License, which permits unrestricted use, distribution, and build upon your work non-commercially.

### Citation:

Kim JS. Reduce the Burden of Polypectomy with Predictable Juvenile Polyp. *Ann Clin Med Case Rep.* 2021; V6(3): 1-5

### 1. Abstract

Juvenile polyps make up 70 to 80% of pediatric colon polyps, of which 60 to 70% are solitary. The average age of diagnosis of polyps is from 2 to 5 years. The treatment of juvenile polyps in children is polypectomy through colonoscopy. Colonoscopy is widely used in pediatric patients, but requires a thorough bowel preparation before the examination and general anesthesia or deep sedation during the examination, and in rare cases can cause complications. The fact that the lumen of intestine is much smaller than that of adults and the need to perform polypectomy is a heavy burden on the endoscopists.

Recently, fecal calprotectin (FC) has been found to be related to juvenile polyps. Using FC and ultrasound, it is possible to accurately predict the presence of juvenile polyps and reduce the burden on the operator by knowing the exact location before the procedure.

This is the first case in Korea to show that FC can be used to screen juvenile polyps in children. The polyp can be localized by performing ultrasound along with the FC. FC levels can increase with the degree of inflammation regardless of number or size of the polyps. Finally, FC can be useful for follow-up as well as diagnosis

of juvenile polyps.

### 2. Introduction

Juvenile polyps are a type of polyp found mainly in the colon of children, and their prevalence occurs in about 2% of all children. Juvenile polyps make up 70 to 80% of pediatric colon polyps, of which 60 to 70% are solitary. The average age of diagnosis of polyps is from 2 to 5 years [1-4]. The most common clinical symptom of juvenile polyps is intermittent and self-limiting gastrointestinal bleeding, but polyps in children are often accompanied by abdominal pain. These polyps usually have a pedunculated shape, and polyps with large peduncles can be pushed up and cause intussusception [1,3,4]. The treatment of juvenile polyps in children is polypectomy through colonoscopy. Colonoscopy is widely used in pediatric patients, but requires a thorough bowel preparation before the examination and general anesthesia or deep sedation during the examination, and in rare cases can cause complications [5]. If there is a way to predict polyps in children through a non-invasive method, it can play an important role in selecting patients who need polypectomy. Fecal calprotectin (FC), which was used in the screening and monitoring of inflammatory bowel disease (IBD), serves as a potential non-invasive biomarker to evaluate the

need of endoscopy for juvenile polyp in pediatric [6, 7].

Here we report the first case of juvenile polyps in Korean children diagnosed and treated with fecal calprotectin. The case report was exempted by the Institutional Review Board with a waiver for the requirement of informed consent (IRB no. PC20ZISI0158).

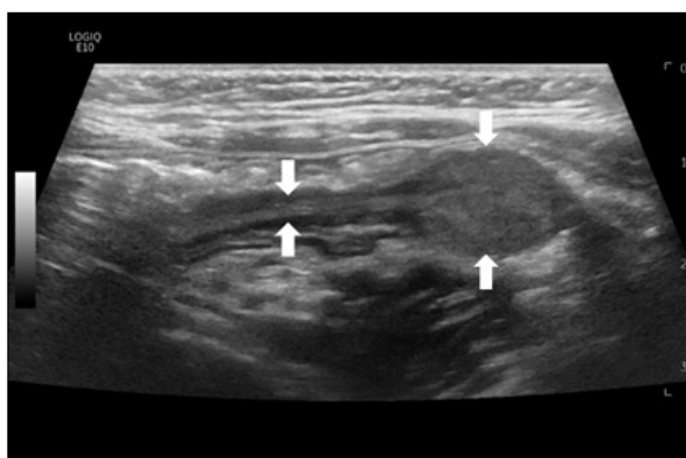
### 3. Case Report

A previous healthy, 34-month-old female presented to the pediatric department of gastroenterology in November 2020 with intermittent bloody stools which was getting worse since June 2019. The patient complained of mild abdominal pain intermittently, and the appearance of the stool was a mixture of blood and tissue. There were no accompanying symptoms such as vomiting, diarrhea, weight loss, fever, and dehydration. The patient visited a local clinic, and took medicine under suspicion of constipation. Symptoms did not improve and the amount of bloody stools gradually increased.

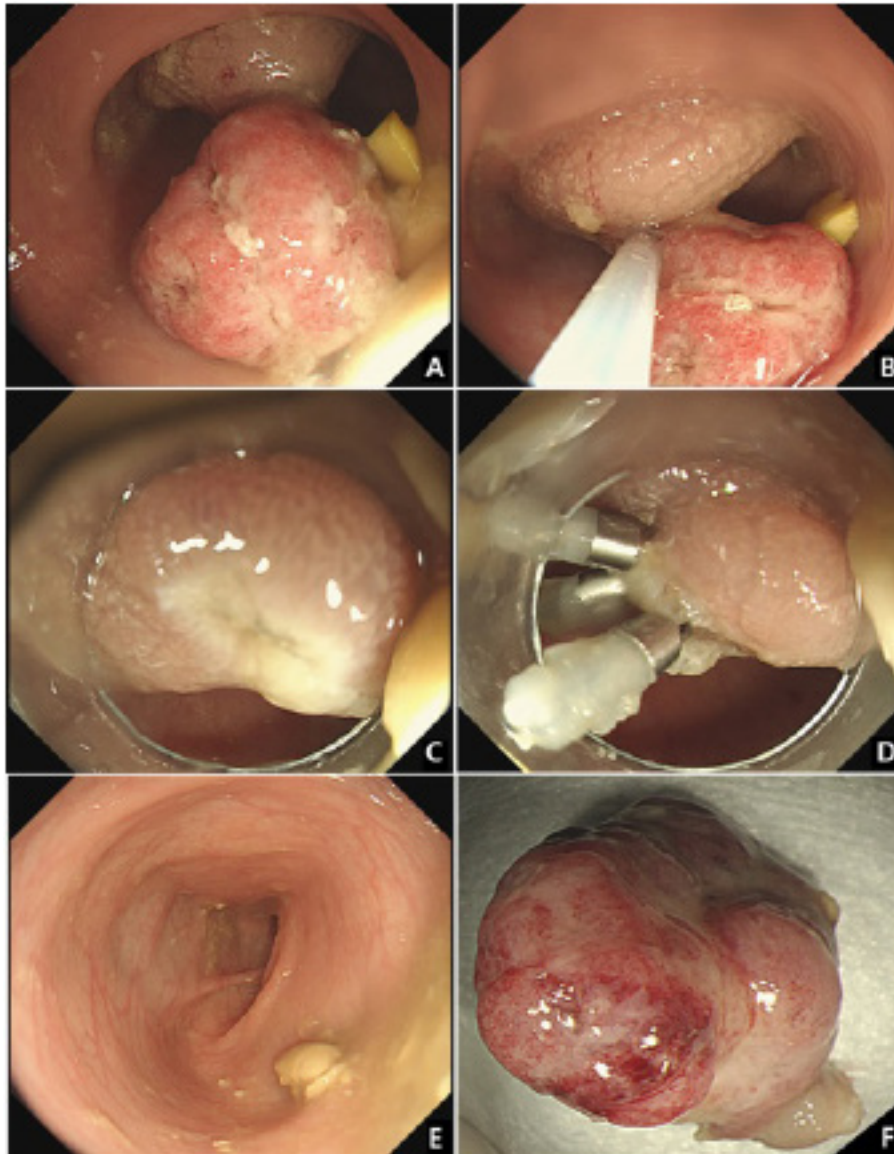
The initial vital signs were as follows; blood pressure, 101/60 mmHg; heart rate, 93 beats per minute; respiratory rate, 22 breaths per minute; and temperature, 36.5 °C. She weighed 11.1kg and physical examination showed mild periumbilical tenderness without rebound tenderness. Digital rectal exam was performed and there was no palpable mass.

Initial laboratory evaluation showed a hemoglobin concentration of 13.2 g/dL, white blood cell count of 8,800 / $\mu$ L (neutrophils, 26%), and platelet count of  $354 \times 10^3$  / $\mu$ L, and C-reactive protein of 0.11 mg/dL, erythrocyte sedimentation rate 4 mm/h, total

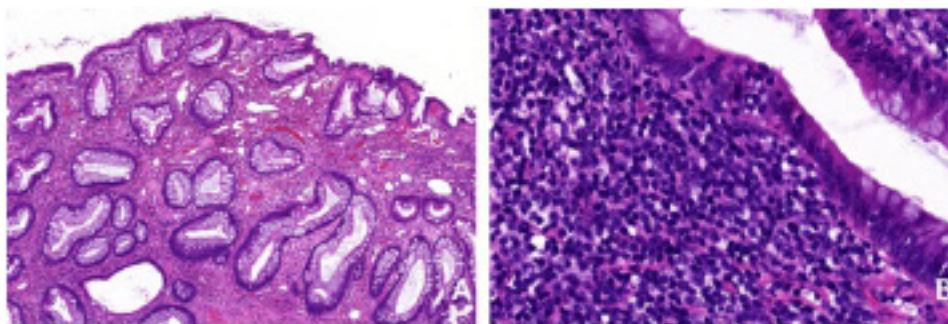
protein 6.8 g/dL, albumin 4.19 g/dL, prothrombin time (PT) international normalized ratio (INR) 1.08, and activated partial thromboplastin time (aPTT) 32.8 sec, which were in normal length. The serum electrolytes, creatinine and liver function tests were all within normal limits. Helicobacter Pylori IgG was negative and stool culture was normal, but occult blood test was increased to 387 ng/ml. FC level was obtained that was abnormally elevated at 2719  $\mu$ g/g (normal <50  $\mu$ g/g). Abdominal ultrasonography revealed a single 1.9 x 1.2 cm oval pedunculated shape mass at left lower colon (Figure 1). Under the impression of juvenile poly, colonoscopy was performed using an electronic videoendoscope (type GIF-H290: Olympus Optical, Tokyo, Japan). Midazolam 0.1 mg/kg was administered before the colonoscopy for deep sedation, and heart rate, respiration rate, and blood pressure were monitored for the patient's safety. The polyp was a pedunculated type and was located 18 cm above the anal verge (Figure 2A). A combination of saline and indigo carmine was used for the submucosal lift (Figure 2B). The polyp was successfully removed with a polypectomy snare (current 20 W for excision, Figure 2C). Three clips were applied to the resected site to prevent delayed bleeding after polypectomy (Figure 2D). There were no additional polyps in the entire colon (Figure 2E), and the polyp were retrieved for histological analysis (Figure 2F), resulting in juvenile polyps with severe inflammation (Figure 3). There were no complications after polypectomy and the patient was discharged 2 days later. One month after polypectomy, FC levels normalized to less than 50  $\mu$ g/g, and the patient had no bloody stool or other gastrointestinal problems.



**Figure 1:** Abdominal ultrasonography revealed a single 1.9 x 1.2 cm oval pedunculated shape mass at left lower colon (arrows).



**Figure 2:** The polyp was a pedunculated type located 18cm above the anal verge (A). A combination of saline and indigo carmine was used for the submucosal lift and the tip of the snare was anchored on the stalk (B). A Complete removal was achieved after the polypectomy and there was no immediate bleeding (C). Three clips were applied to the resected site to prevent delayed bleeding (D). There were no additional polyps in the entire colon (E). Resected specimen was retrieved and the size was 1.9 cm (F).



**Figure 3:** Histologic findings showed dilated crypts and surface erosion, typical of juvenile polyps (A, hematoxylin-eosin, 20 $\times$ ). It showed severe inflammation in the tissue (B, hematoxylin-eosin, 40 $\times$ )



#### 4. Discussion

Calprotectin is known as an antimicrobial protein and mainly constitutes up to 60% of the proteins in the cytoplasm of neutrophils [8]. In addition, it is distributed in the cytoplasm of monocytes, macrophages, and granulocytes [9]. FC is mainly used in screening and monitoring IBD patients such as Crohn's disease and ulcerative colitis. The mechanism of calprotectin release into the gastrointestinal is activated by increasing leukocyte recruitment through the interaction of monocytes and endothelial cells, and through pro-inflammatory chemokines which activate phagocytes to further promote the outflow of leukocytes to the inflammatory bowel [10]. Detection of this protein in feces is suspected as a result of cell death and destruction [11]. Elevated FC level are also detectable in infectious diarrhea, eosinophilic colitis, colorectal cancer, and non-steroidal anti-inflammatory drugs enteropathy [12-14].

Recently, FC has been found to be useful for screening juvenile polyps. The increase in FC levels in juvenile polyps is due to the high presence of inflammatory cells within the polyp. Olafsdottir et al reported that children with juvenile polyps had elevated fecal calprotectin levels, but lower levels than those with active inflammatory bowel disease [7]. However, in our case, FC level was as high as those with inflammatory bowel disease. Previous studies suggested that the size and number of polyps were associated with an increase in calprotectin [6,15]. The larger the number and size of polyps, the higher the calprotectin was increased. However, in our patient, there was only one polyp and the size was 1.9cm, which was smaller than the previous study, but the inflammation level was >2500 ug/ml. This can be said that regardless of the number or size of the polyps, the severity of inflammation in the polyps itself was associated with an increase in calprotectin.

The use of colonoscopy in children always implies the risk of sedation-related complications. In particular, juvenile polyps occur at a young age between 2 and 5 years of age, and the fact that the lumen of intestine is smaller than that of adults and the need to perform polypectomy is a heavy burden on the gastrointestinal endoscopists. Our patient used an upper gastrointestinal endoscopy because the intestinal diameter was so narrow. Therefore, it is possible to reduce the burden on the operator by accurately predicting the presence of juvenile polyps and knowing the exact location before the procedure. For this reason, ultrasound is recently recognized as a primary test for high safety and accuracy as a screening for juvenile polyps in children [16]. In the case of juvenile polyps, they are most commonly located in the left lower colon and rectum [6,14]. The causes of false negatives include the operator's skill level, relatively small polyp size, and polyps located in the rectum [17]. According to Qu et al, when enema is performed before ultrasound, the polyp detection rate reaches up to 97% [16]. Because our patient did not perform enema prior to ultrasound, the entire

colon including the rectum was evaluated precisely during endoscopy, but there were no additional polyps.

Before the polypectomy, combination of saline and indigo carmine was used for the submucosal lift, and the clip was fixed at the resected site. In previous studies, this method can reduce post-polypectomy complications [18]. In children, the routine use of prophylactic methods during standard polypectomy procedure can reduce complications.

As in the previous study, in our case, children with juvenile polyps showed normalized FC levels after polypectomy [7]. This suggests that FC is not only useful for screening the existence of juvenile polyps, but also a useful tool for evaluating complete removal of all polyps and the possibility of recurrence of polyps in patients undergoing polypectomy [18].

#### 5. Conclusion

In conclusion, this is the first case in Korea to show that FC can be used to screen juvenile polyps in children. The polyp can be localized by performing ultrasound along with the FC. FC levels can increase with the degree of inflammation regardless of the number or size of the polyps. Complications can be reduced by using prophylactic submucosal lift during the polypectomy. Finally, FC can be useful for follow-up as well as diagnosis of juvenile polyps.

#### References

1. Thakkar K, Fishman DS, Gilger MA. Colorectal polyps in childhood. *Curr Opin Pediatr.* 2012; 24(5): 632-7.
2. Fox VL, Perros S, Jiang H, Goldsmith JD. Juvenile polyps: recurrence in patients with multiple and solitary polyps. *Clin Gastroenterol Hepatol.* 2010; 8(9): 795-9.
3. Durno CA. Colonic polyps in children and adolescents. *Can J Gastroenterol.* 2007; 21(4): 233-9.
4. Adolph VR, Bernabe K. Polyps in children. *Clin Colon Rectal Surg.* 2008; 21(4): 280-5.
5. Tringali A, Thomson M, Dumonceau JM, Tavares M, Tabbers MM, Furlano R, et al. Pediatric gastrointestinal endoscopy: European Society of Gastrointestinal Endoscopy (ESGE) and European Society for Paediatric Gastroenterology Hepatology and Nutrition (ESPGHAN) Guideline Executive summary. *Endoscopy.* 2017; 49(1): 83-91.
6. Pauley-Hunter RJ, Kunnath S, Wolff K, Vanderhoof JA. Fecal calprotectin and pediatric juvenile polyps. *J Pediatr Gastroenterol Nutr.* 2015; 60(4): e30-1.
7. Olafsdottir I, Nemeth A, Lorinc E, Toth E, Agardh D. Value of Fecal Calprotectin as a Biomarker for Juvenile Polyps in Children Investigated With Colonoscopy. *J Pediatr Gastroenterol Nutr.* 2016; 62(1): 43-6.
8. Roca M, Rodriguez Varela A, Carvajal E, Donat E, Cano F, Armisen A, et al. Fecal calprotectin in healthy children aged 4-16 years. *Sci Rep.* 2020; 10(1): 20565.

9. Rugtveit J, Brandtzaeg P, Halstensen TS, Fausa O, Scott H. Increased macrophage subset in inflammatory bowel disease: apparent recruitment from peripheral blood monocytes. *Gut*. 1994; 35(5): 669-74.
10. Nisapakultorn K, Ross KF, Herzberg MC. Calprotectin expression inhibits bacterial binding to mucosal epithelial cells. *Infect Immun*. 2001; 69(6): 3692-6.
11. Voganatsi A, Panyutich A, Miyasaki KT, Murthy RK. Mechanism of extracellular release of human neutrophil calprotectin complex. *J Leukoc Biol*. 2001; 70(1): 130-4.
12. Chen C-C, Huang J-L, Chang C-J, Kong M-SJJopg, nutrition. Fecal calprotectin as a correlative marker in clinical severity of infectious diarrhea and usefulness in evaluating bacterial or viral pathogens in children. *J Pediatr Gastroenterol Nutr*. 2012; 55(5): 541-7.
13. Tibble J, Sigthorsson G, Foster R, Scott D, Fagerhol M, Roseth A, et al. High prevalence of NSAID enteropathy as shown by a simple faecal test. *Gut*. 1999; 45(3): 362-6.
14. Olafsdottir I, Nemeth A, Lörinc E, Toth E, Agardh DJJopg, nutrition. Value of fecal calprotectin as a biomarker for juvenile polyps in children investigated with colonoscopy. *J Pediatr Gastroenterol Nutr*. 2016; 62(1): 43-6.
15. Khan F, Mani H, Chao C, Hourigan S. Fecal Calprotectin as a Future Screening Tool for Large Juvenile Polyps. *Glob Pediatr Health*. 2015; 2: 2333794X15623716.
16. Qu NN, Liu RH, Shi L, Cao XL, Yang YJ, Li J. Sonographic diagnosis of colorectal polyps in children: Diagnostic accuracy and multi-factor combination evaluation. *Medicine (Baltimore)*. 2018; 97(39): e12562.
17. Hosokawa T, Hosokawa M, Tanami Y, Sato Y, Nambu R, Iwama I, et al. Diagnostic performance of ultrasound without any colon preparation for detecting colorectal polyps in pediatric patients. *Pediatr Radiol*. 2019; 49(10):1306-12.
18. Di Nardo G, Esposito F, Ziparo C, Strisciuglio C, Vassallo F, Di Serafino M, et al. Faecal calprotectin and ultrasonography as non-invasive screening tools for detecting colorectal polyps in children with sporadic rectal bleeding: a prospective study. *Ital J Pediatr*. 2020; 46(1): 66.