

A Case of Delayed-Onset Paraplegia at 7 Days After Thoracic Endovascular Aortic Repair

Yuriko Tanabe¹, Takashi Shuto¹, Noritaka Kamei², Norio Hongo² and Shinji Miyamoto^{1*}

¹Department of Cardiovascular Surgery, Faculty of Medicine, Oita University 1-1 Idaigaoka, Hasama-cho, Yufu-shi. Oita 879-5593, Japan

²Department of Radiology, Faculty of Medicine, Oita University 1-1 Idaigaoka, Hasama-cho, Yufu-shi. Oita 879-5593, Japan

*Corresponding author:

Shinji Miyamoto,
Department of Cardiovascular surgery, Oita University
Faculty of Medicine 1-1 Idaigaoka, Hasama-cho,
Yufu-shi. Oita 879-5593, Japan, Tel: +8197-586-6732,
Fax: +8197-586-6739,
E-mail address: smiyamot@oita-u.ac.jp

Received: 20 Oct 2021

Accepted: 27 Oct 2021

Published: 03 Nov 2021

J Short Name: ACMCR

Copyright:

©2021 Shinji Miyamoto. This is an open access article distributed under the terms of the Creative Commons Attribution License, which permits unrestricted use, distribution, and build upon your work non-commercially.

Citation:

Shinji Miyamoto, A Case of Delayed-Onset Paraplegia at 7 Days After Thoracic Endovascular Aortic Repair. *Ann Clin Med Case Rep.* 2021; V7(13): 1-4

Keywords:

Paraplegia; TEVAR, Thoracoabdominal aorta

1. Abstract

Paraplegia after thoracic endovascular aortic repair (TEVAR) is a common complication, but it is rare for it to occur at 1 week after TEVAR. We describe a patient with delayed-onset paraplegia that occurred 7 days after TEVAR. A 76-year-old woman had a thoracoabdominal aortic aneurysm and abdominal aortic aneurysm. She had undergone Y-graft replacement and visceral debranching surgery. Two years later, because of enlargement of thoracoabdominal aneurysm, we performed TEVAR. Her postoperative progress was satisfactory, but 7 days after TEVAR, she suddenly developed paraplegia. We performed spinal drainage and administered medication. Subsequently, her paraplegia was relieved. She was discharged with mild muscle weakness. General preventive methods are performed intraoperatively or during the early postoperative period to prevent paraplegia; however, physicians should keep in mind that paraplegia can occur at any time after TEVAR.

2. Introduction

Thoracic endovascular aortic repair (TEVAR) has been actively implemented as a less invasive treatment for abdominal aortic and thoracic aortic aneurysm. However, some cases of postoperative spinal cord ischemia, which is one of the serious complications after TEVAR, have been reported [1]. Causes of spinal cord ischemia include blockade of the Adamkiewicz artery, blocked collat-

eral circulation, postoperative hypotension, increased cerebrospinal fluid pressure, and so on [2]. Since TEVAR is a technique that cannot be used to reconstruct the intercostal artery, unlike conventional open surgery, postoperative spinal cord blood flow depends on collateral circulation.

Various measures for preventing spinal cord ischemia have been attempted, but postoperative spinal paralysis is still an important topic. The incidence of spinal cord ischemia after TEVAR ranges from 0 to 12% [3-6]. The average time from operation to spinal cord ischemia is 10.6 hours [1]. We describe a patient with delayed-onset paraplegia that occurred 7 days after TEVAR just before discharge.

3. Case Report

A 76-year-old woman had a thoracoabdominal aortic aneurysm and an abdominal aortic aneurysm. She had a history of ovariectomy, cholecystectomy, and angina pectoris. We performed Y-graft replacement surgery to treat the abdominal aortic aneurysm and debranching of the visceral branches for the future treatment of the thoracoabdominal aortic aneurysm by TEVAR. Because it was difficult to reach the proximal celiac artery due to adhesion, we had to leave the celiac artery root open and bypass it to the splenic artery (Figure 1).

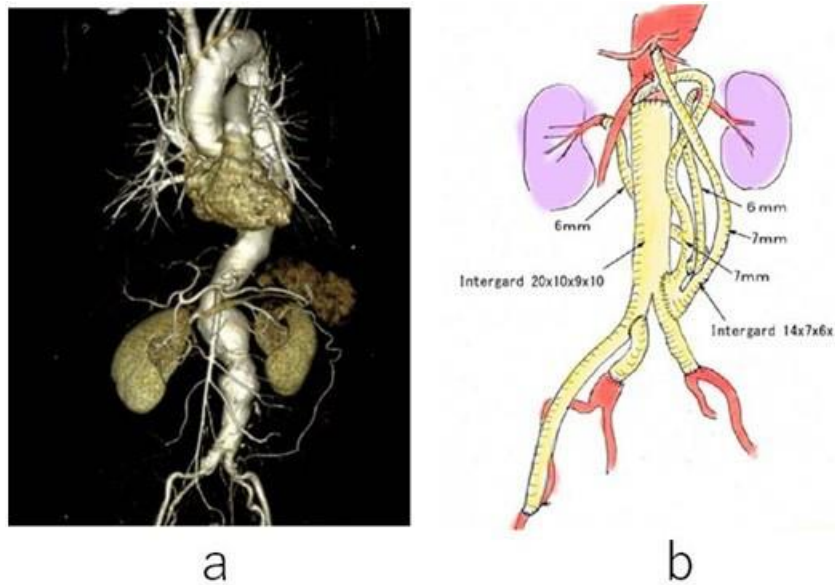


Figure 1: Enhanced computed tomography shows a thoracoabdominal and abdominal aneurysm(a). A schema of the first debranching operation(b). Computed tomography scans before surgery (left) and after surgery (right).

Two years later, she experienced chest pain and computed tomography (CT) revealed enlargement of the thoracoabdominal aortic aneurysm (58mm). The bypass to the celiac artery was occluded but other debranching grafts were patent. (Figure 2). Preoperative angiography confirmed connection between the common hepatic artery and the SMA.

TEVAR was performed under local anesthesia to treat the thoracoabdominal aortic aneurysm without spinal drainage. The celiac artery was covered with a Gore Excluder Aortic Extender (36 mm/4.5 cm; WL Gore & Associates). Three Valiant Thoracic devices (30 mm/185 mm, 32 mm/185 mm, 34 mm/212 mm; Medtronic Inc.) were placed from the Y-graft to just below the origin of the left subclavian artery. No endoleak was observed (Figure 3).

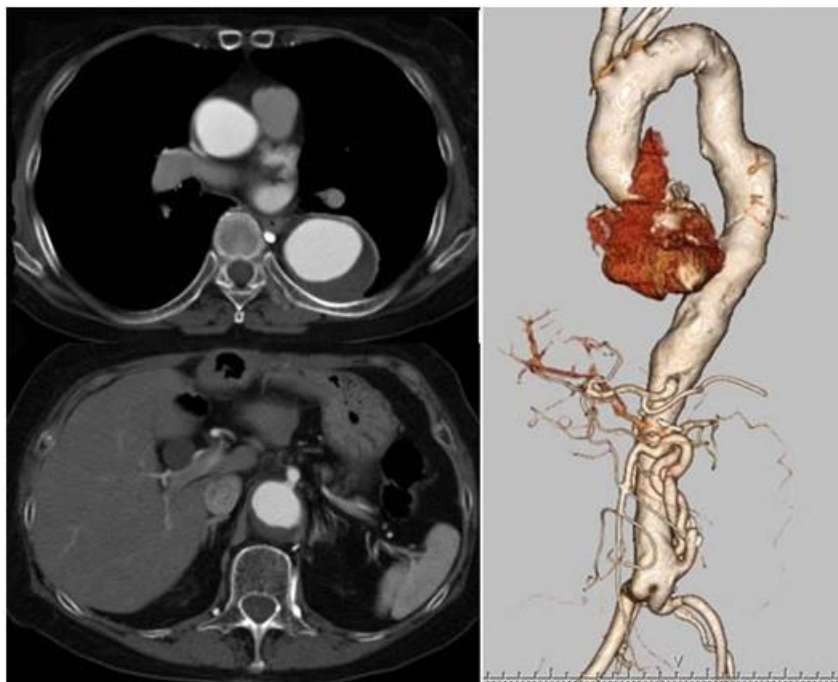


Figure 2: Enhanced computed tomography scan before TEVAR shows a large thoracoabdominal aneurysm and occlusion of a bypass graft to the celiac artery.

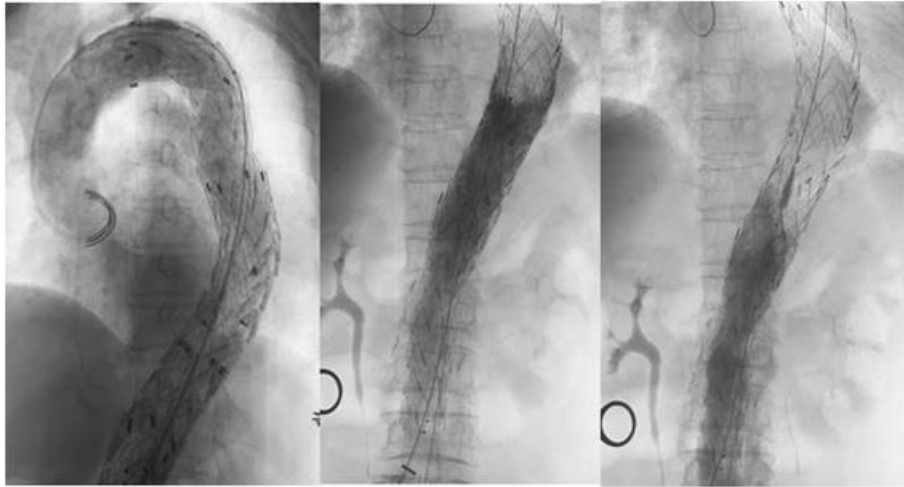


Figure 3: Intraoperative angiography shows no visible endoleak.

Postoperatively, no muscle weakness of the lower limbs was observed. 1 day after operation she was walking around the ward without any abnormal feeling. Subcutaneous hemorrhage in the right groin occurred on postoperative day 2 and disseminated intravascular coagulation (DIC) was suspected. Therefore, we increased the dose of tranexamic acid from 750mg/day to 1500mg/day. Her mean blood pressure was maintained over 80 mmHg. On postoperative day 7, she suddenly complained of strong pain in both lower limbs but was still able to walk. Her blood pressure at that time was 175/76 mmHg, and the pain reached her waist within 1 hour after onset. Over time, paraplegia developed and was completed in 2 hours after onset.

After administration of steroid and edaravone, emergent spinal fluid drainage was performed. Slight improvement in the patient's ankle joint was already seen when entering the operating room (before drainage), and the sensation of pain in the lower limb improved when she returned to the ward. The volume of spinal fluid drained was about 60 ml/day in the first day. Hyperbaric oxygen therapy was started next day. Spinal drainage was discontinued on postoperative day 10 because the paraplegic symptoms were almost resolved. Magnetic resonance imaging performed on postoperative day 11 showed no evidence of spinal cord infarction. The patient was able to walk on a flat surface but had remaining a little muscle weakness from the left hip to thigh until transferred to a medical facility for further rehabilitation on postoperative day 34.

4. Discussion

TEVAR is a less invasive method of treating thoracic aortic aneurysm compared to conventional open surgery, which can be performed mainly for high-risk patients. However, the incidence of paraplegia is not so low after TEVAR even compared with after open surgery [7]. The average time of spinal cord ischemia from TEVAR to onset is 10.6 hours [1]. A case of paraplegia occurring at 1 week after TEVAR is very rare.

We all know that the cause of postoperative paraplegia is ischemia of the spinal cord. However, it is impossible to reconstruct direct blood circulation such as reconstruction of the Adamkiewicz artery during TEVAR, whereas direct revascularization can be done during open surgery. Therefore, avoidance of paraplegia depends largely on the development of collateral circulation, especially after TEVAR. Preventive methods, such as maintenance of hypertension, sufficient oxygen supply, and prophylactic spinal cord drainage have been employed. These methods are performed during the intraoperative to early postoperative period [8]. In most cases, there is already sufficient collateral circulation during TEVAR. Even if collateral circulation is poor, it is conceivable that ironically troublesome endoleaks would support spinal blood supply leading to prevention of paraplegia.

In the present case, TEVAR was wide ranging, as it covered all the intercostal and lumbar arteries, but the patient showed no spinal disorder perioperatively. We presume that spinal circulation had to be maintained by support of some endoleaks that were not clear on intraoperative angiography. This patient developed delayed paraplegia suddenly even in a good hemodynamic condition, suggesting that a fine endoleak may have remained for a while due to postoperative DIC and then disappeared along with improvement of DIC. If the collateral circulation was adequate to maintain spinal circulation independently of the endoleak, the patient would not have developed paraplegia with sufficient blood pressure.

In this case, complete paraplegia developed within 2 hours after onset, but signs of symptomatic improvement were already seen just before spinal cord drainage. Therefore, we infer that not only spinal cord drainage but also the rapid development of collaterals improved paraplegia. If the endoleak had disappeared slowly until collateral circulation was sufficient, the patient may not have developed paraplegia. We and the patient were lucky in the first place because she had been already fine but hadn't been discharged yet.

5. Conclusion

Generally, some preventive methods of paraplegia are performed intraoperatively or during the early postoperative period. However, physicians should keep in mind that paraplegia can occur at any time after TEVAR even under a good hemodynamic condition, especially when DIC exists in the early postoperative phase.

References

1. Ulley BW, Cheung AT, Fairman RM, Jackson BM, Woo EY, Bavaria J et al. Risk factors, outcomes, and clinical manifestations of spinal cord ischemia following thoracic endovascular aortic repair. *J Vasc Surg.* 2011; 54: 677-84.
2. Cheung AT, Weiss SJ, McGarvey ML, Strecker MM, Hogan MS, Escherich A et al. Interventions for reversing delayed-onset postoperative paraplegia after thoracic aortic reconstruction. *Ann Thorac Surg.* 2002; 74: 41309; 420-1.
3. Kakinohana M. What should we do against delayed onset paraplegia following TEVAR? *J Anesth.* 2014; 28: 1-3.
4. Greenberg R, Resch T, Nyman U, Lindh M, Brunkwall J, Brunkwall P et al. Endovascular repair of descending thoracic aortic aneurysms: an early experience with intermediate-term follow-up. *J Vasc Surg.* 2001; 31: 147-56.
5. White RA, Donayre CE, Walot Z, Lippmann M, Woody J, Lee J. et al. Endovascular exclusion of descending thoracic aortic aneurysms and chronic dissections: initial clinical results with the AneuRx device. *J Vasc Surg.* 2001; 33: 927-34.
6. Amabile P, Grisoli D, Giorgi R, Bartoli JM, Piquet P. Incidence and determinants of spinal cord ischaemia in stent-graft repair of the thoracic aorta. *Eur J Vasc Endovasc Surg.* 2008; 35: 455-61.
7. Yanase Y, Kawaharada N, Maeda T, Koyanagi T, Ito T, Kurimoto Y et al. Treatment of delayed neurological deficits after surgical repair of thoracic aortic aneurysm. *Ann Thorac Cardiovasc Surg.* 2012; 18: 271-4.
8. Bobadilla JL, Wynn M, Tefera G, Acher CW. Low incidence of paraplegia after thoracic endovascular aneurysm repair with proactive spinal cord protective protocols. *J Vasc Surg.* 2013; 57: 1537-42.