

Management of Shunt complication in a Paediatric COVID 19 Case in Bangladesh

Medical College Hospital

Huda N* Gomes VC, Chowdhury M and Hamid R

Indoor Medical Officer Department of Neurosurgery, Bangladesh Medical College Hospital, Bangladesh

*Corresponding author:

Md. Nazmul Huda,
Indoor Medical Officer Department of
Neurosurgery, Bangladesh Medical College
Hospital, Bangladesh,
E-mail: chessmate81@gmail.com

Received: 22 Jan 2022

Accepted: 07 Feb 2022

Published: 14 Feb 2022

J Short Name: ACMCR

Copyright:

©2022 Huda N. This is an open access article distributed under the terms of the Creative Commons Attribution License, which permits unrestricted use, distribution, and build upon your work non-commercially.

Citation:

Huda N, Management of Shunt complication in a Paediatric COVID 19 Case in Bangladesh Medical College Hospital. Ann Clin Med Case Rep. 2022; V8(9): 1-5

Keywords:

Gut perforation; Ventricular surgery; COVID 19

1. Abstract

V-P shunt is the most common surgery done in paediatric hydrocephalus. Though the surgery remains as 'minor' in the arena of Neurosurgery, its complication surpass any boundary. Here we discuss a case of shunt complication which had malfunctioning shunt with both end malposition, cranial end occluded by septum and cortex and peritoneal end invading bowel. Surgery was taking a new course for dramatic appearance of COVID 19.

2. Abbreviations: CSF- cerebro spinal fluid, VP shunt- ventriculo peritoneal shunt; ICP- intracranial pressure; DRE- digital rectal examination; EVD- external ventricular drain; SARS-CoV-2: severe acute respiratory syndrome coronavirus 2

3. Introduction

Hydrocephalus is a medical condition characterized by the pathological dilatation of the ventricular system of the brain resulting from inadequate passage of cerebrospinal fluid from its point of production within the cerebral ventricles to its point of absorption into the systemic circulation (most commonly due to aqueductal stenosis). Hydrocephalus may also occur due to CSF overproduction or defective absorption of CSF (most often, includes conditions such as intracranial haemorrhage or meningitis resulting in damage to the arachnoid granulations, where CSF is reabsorbed), or venous drainage insufficiency [1].

Multiple lines of treatment for the management of hydrocephalus have been proposed including medical and surgical strategies. Nonetheless, surgical CSF diversion procedures have shown superiority as a long-term treatment and have been considered the treatment of choice since the 1950s [2,3]. Different diversion

techniques have been developed since 1905, including intracranial bypass ventricular septostomy, third ventriculostomy and extracranial CSF shunting with implantation of valvular systems [4]. Widely adopted surgical procedure for the treatment of this condition is the placement of V-P shunt [5]. Like all other surgeries, V-P shunt surgery also has its own complications, distal end shunt malfunction, secondary to migration of the abdominal end, exposed shunt reservoir, exposed distal catheter, shunt obstruction, [6,7] large bowel perforation is a rare complication with incidence of 0.1-0.7% [8].

The coronavirus disease 2019 (COVID-19) has given rise to an unprecedented challenge to public health, medical communities, overall healthcare services worldwide. Likewise, COVID-19 pandemic has had a major effect on paediatric neurosurgery. As appropriate diagnosis is very much challenging in the paediatric population and also due to their invasive nature, surgeries create concern for widespread disease transmission between patients and healthcare workers [9]. Beside the risk of high transmission, it has been seen that patients who are infected with COVID-19 are at a great risk in poor clinical outcome following surgery. Urgent neurosurgical interventions for paediatric patients with SARS-CoV-2 are rare. Different studies have shown that children appear to be less commonly affected by SARS-CoV-2 infection than adults, and to be more commonly asymptomatic [10,11,12]. We report an unusual case where both cranial and distal end were found in malposition and delaying of the treatment due to patient being infected with COVID 19. We present our institutional experience, treatment dilemma, surgical management and outcomes of the patient.

4. Case Report

A 2-year-old boy presented with two times appearance of the distal end of v-p shunt tube through the anus, as presumed by the mother. The suspected whitish yellow worm like structure did not show any water dripping. During this period the parents also noticed increase in OFC about 2cm within 2 months. The child was treated for congenital hydrocephalus 18 months back with a medium pressure Chhabra shunt. His parents complained of delayed speech and inability to walk without support. On general examination baby was mildly anemic, non-icteric, no lymphadenopathy, abdomen was soft, non-tender, and no organomegaly, bowel and bladder function normal. On inspection and DRE revealed no polyp, hemorrhoid or distal end of shunt. On neurological examination, the child was active and playful, sensation intact and all reflexes were normal except the child was unable to walk without support with signs of right sided hemiparesis. He was investigated with plain X-ray abdomen in erect posture (Figure 2), which showed the distal end of shunt tube in normal position, no sign of perforation (peritonitis) or free gas shadow under diaphragm was seen. A brain CT scan was also advised (Figure 1), which revealed apparently underworking shunt with left fronto-temporo parietal porencephalic cyst with hydrocephalus and cranial tip of V-P shunt burrowed within septum and frontal cortex of opposite side with moderate pressure effect. As there were no obvious clinical or radiological features of peritonitis. Initially our plan was only shunt revision. But during revision both ends was found non-working and removal of the peritoneal end revealed soiling with fecal matter (Figure 3). But unfortunately, the cranial end could not be removed even with cauterization, as it was strictly adhered in intraventricular septum and we placed an EVD (Figure 4). So we had to leave the cranial end in place along with the valve and cut the rest of the shunt. The peritoneal end of the shunt was sent for culture sensitivity test along with CSF.

In immediate post-operative period we started empirical antibiotics. From 2nd POD baby developed high grade fever and antibiotics were switched according to C/S report. Thereafter within 2-3 days baby gradually became afebrile and overall clinical condition improved. On 7th POD we planned to remove the cranial end but as the baby tested covid positive though asymptomatic, so the surgery was deferred. As he was asymptomatic for covid, we thought delaying infected cranial end removal is not wise. We planned for the second surgery on 10 days of COVID-19, which was endoscope guided removal of cranial end of the shunt but this attempt failed as well due to strict adherence of the cranial end into the septum (Figure 5). So we had to go for craniotomy to remove the cranial end (Figure 6). Previous EVD was removed and a new EVD was left at the craniotomy site. On post-operative period the CSF was reddish in color. So ventricular wash was given on two episodes at 4th and 7th POD after ventricular surgery. But as the color was not changing, we started Tranexamic Acid orally once

daily and continued for 3 days. Consequently, CSF color turned straw from red (Figure 7). Then we repeated CSF Cytology and Biochemistry test which was within normal physiological limit, so finally we planned for revision V-P shunt procedure. After 1 week, he was taken up for a shunt revision surgery with removal of EVD. Postoperatively, no further X ray or CT scan was done. The child had an uneventful recovery, was started on oral feeds and discharged after 10 days.

4.1. Follow up after 6 months: Child is walking without support and speech is more fluent. He caught up all developmental milestones for his age.

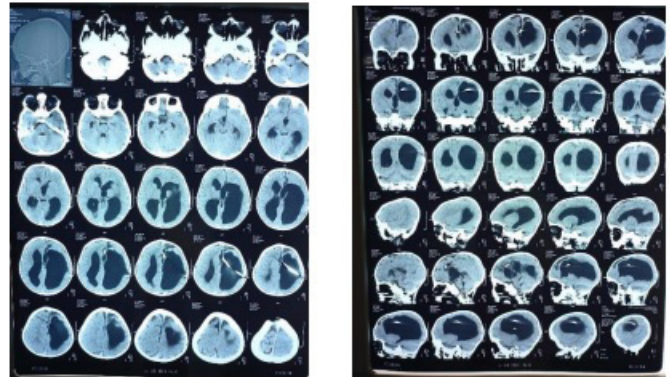


Figure 1: CT scan of brain showing malposition of cranial end of V-P shunt.

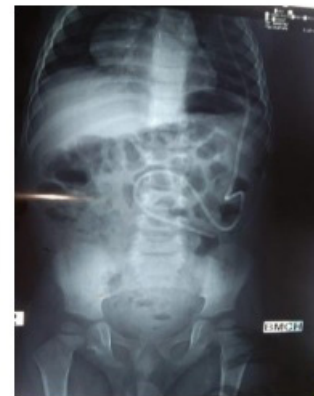

Figure 2: X-ray abdomen

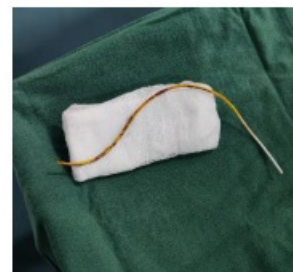


Figure 3: Peritoneal end of shunt soiled with fecal matter.

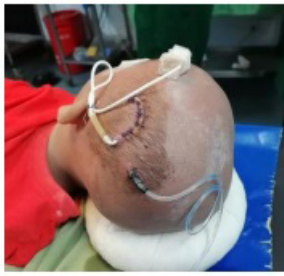

Figure 4: In operative room before 2nd surgery.

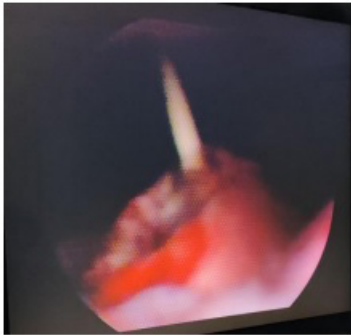


Figure 5: Burrowed cranial end of shunt as seen through endoscope



Figure 6: Removed cranial end.



Figure 7: Change of CSF color from red to straw/orange color.

5. Discussion

Ventriculoperitoneal shunts are routinely placed for the management of hydrocephalus. The epidemiology of shunt malposition is not well known. The complications related to VP shunt implantation are reported to occur in 24%-47% of the cases [13,14]. Many of these complications require shunt revisions. Removal of

the shunt (if infected) followed by creating alternative pathway for shunt drainage with administration of intraventricular empirical antibiotics delivers good result [15]. Malposition of both end of a VP shunt is quite unusual. Shunt malfunction is caused by occlusion of flow along the shunting device. The most common place for shunt malfunction occurs near the ventricular catheter from in growth of choroid plexus or other debris into the catheter. Though rare, adherence of cranial end within the brain parenchyma could also be possible due to excessive insertion of the catheter. On the other hand, distal end occlusion in the peritoneal space can be precipitated by tissue ingrowth into the distal shunt tube [16]. According to the statistics of different studies, it has already been speculated that, within 2 years of V-P shunt surgery, approximately 50% malfunction is seen in the proximal end, around 14% in distal end and 10% malfunction attributes directly to valve [14]. Though rare but gut perforation is a dreadful complication of V-P shunt surgery. It occurs in up to 2% of the cases and in majority of the cases the gut perforation does not produce any sign symptoms of peritonitis. It has high mortality rate around 15% [18]. Colon is the most common site for perforation, although perforation of the small bowel, stomach, and other hollow viscus has also been reported [6,14,19,20,21]. Children are more susceptible to intestinal perforation due to weak bowel musculature [22]. There are different mechanisms through which gut can be perforated, such as, pressure necrosis of intestinal wall by the tube, foreign body reaction and silicon tube allergy. The perforation of the bowel lumen can also occur when the freely moving catheter gets adherent to the serosa of a viscus and the bevelled end of the tube, combined with the continuous water hammer effect of the CSF pulsations, penetrate the walls, and eventually perforate the viscus. Thereafter, the peristaltic waves drive the “foreign body” forward [23,25]. In the present case, a medium pressure Chhabra shunt was implanted for hydrocephalus that developed as a complication of obstruction of the shunt due to burrowing of the cranial end in brain parenchyma and silent perforation into colon of peritoneal end.

In our case, the patient was operated for the malfunctioning of the VP shunt. He showed symptoms of raised ICP. Our initial suspicion was malfunctioning of the shunt due to perforation of the gut by the tip of peritoneal end of the shunt because the mother presumed 2 times appearance of tube like structure per rectally, though she did not notice any water dripping through it. No clinical features of perforation or peritonitis was seen. It is important to note that, over 50% of patients with VP shunt gut perforations are asymptomatic with the most common presentation being the distal end of the shunt protruding out of the anus, in our case we did not noticed any such protrusion [8,24]. On radiological examination, X ray abdomen did not showed gas under diaphragm. There was no knotting of the shunt tube seen and there were no clinical features of peritonitis and as the radiological report showed no abnormality and clinically baby's abdomen and DRE was quiet normal,

we ruled out gut perforation. But in retrograde analysis of X ray we found relevant points regarding silent gut perforation, such as distal end of the catheter following the tract of large bowel, tip of peritoneal end of catheter going well beyond the pubic symphysis, in our case, it was just above the pelvis [25]. However, the shunt seemed to be underworking according to CT scan images of the brain. So plan for revision of shunt was taken. Shunt malfunctioning case like this one, needs a series of management beginning from removing the shunt followed by exteriorization, control of infection and reinsertion of the shunt at an appropriate time. Asymptomatic cases without meningitis and peritonitis can be managed smoothly but in the era of pandemic, patients infected with COVID-19 takes new turn. Migrated shunts per colon are managed simply by removing the shunt per anus, after disconnecting the shunt tube in the neck. Rest of the shunt system can then be removed through parieto-occipital incision. This avoids further hazard and laparotomy [26].

Since we were not sure of gut perforation, removal of the shunt per anus was avoided. During removal of the shunt, we discovered the peritoneal end of the shunt was entirely soiled with fecal matter. This proved his bowel/colon being perforated by the peritoneal end of the shunt. He had neither features of peritonitis before the shunt removal nor developed during postoperative period, and therefore, it was managed well without laparotomy.

Complete removal of the shunt was not possible due to entanglement of the cranial end of the shunt. We did exteriorization, started intraventricular antibiotic Vancomycin via the EVD and continued intra venous antibiotics as well.

The possible reason for cranial end of shunt adherence within the brain parenchyma might be due to excessive insertion of the ventricular catheter. The simplest and safest way to avoid this complication is to take appropriate measurement of the ventricular catheter from CT scan images. On another note, this patient was diagnosed with COVID 19 during his treatment. Baby had 3 consecutive surgeries in the same admission period. The 2nd surgery (craniotomy) was performed while the baby was on 10th day of COVID-19 positive. Acute respiratory failure has been the most common complication of COVID-19 in adults. In contrast, children generally experience a mild illness [10,11,12] There is a chance of clinical deterioration following surgery who requires endotracheal anaesthesia in the COVID-19 affected paediatric population [24]. Complications like laryngospasm, bronchospasm, hypoxaemia can occur [27]. Fortunately, no major complication developed due to anaesthesia, delaying of surgery or surgery itself.

6. Conclusion

Any worm like structure through anus of a shunted baby needs careful evaluation. Surgeons must be experienced enough regarding length of cranial end. Drawing any conclusion regarding emergency surgery in active covid pediatric group demand further studies.

<http://acmcase reports.com>

References

1. Dandy WE. Internal hydrocephalus. An experimental, clinical and pathological study. *Am J Dis Child*. 1914; 8: 406-482.
2. Nulsen F. Treatment of hydrocephalus by direct shunt from ventricle to jugular vein. *Surg Forum*. 1951; 399-403.
3. Braley S. The silicones as subdermal engineering materials. *Ann New York Acad Sci*. 1968; 146(1): 148-157.
4. Rachel RA. Surgical treatment of hydrocephalus: a historical perspective. *Pediatr Neurosurg*. 1999; 30(6): 296-304.
5. Patwardhan RV, Nanda A. Implanted ventricular shunts in the United States: the billion-dollar-a-year cost of hydrocephalus treatment. *Neurosurgery*. 2005; 56(1): 139-144.
6. Ghritlaharey RK, Budhwani KS, Shrivastava DK. Transanal protrusion of ventriculo-peritoneal shunt catheter with silent bowel perforation: report of ten cases in children. *Pediatr Surg Int*. 2007; 23(6): 575-580.
7. Hamdan AR. Ventriculoperitoneal shunt complications: a local study at Qena University Hospital: a retrospective study. *Egypt J Neurosurg*. 2018.
8. Sathyanarayana S, Wylen EL, Baskaya MK. Spontaneous bowel perforation after ventriculoperitoneal shunt surgery: case report and a review of 45 cases. *Surg Neurol*. 2000; 54(5): 388-396.
9. Dedeilia A, Esagian SM, Ziogas IA, Giannis D, Katsaros I, Tsoulfas G, et al. Pediatric surgery during the COVID-19 pandemic. *World J Clin Pediatr*. 2020; 9(2): 7-16.
10. Alnajjar AA, Dohain AM, Abdelmohsen GA, Alahmadi TS, Zaher ZF, Abdelgalil AA, et al. Clinical characteristics and outcomes of children with COVID-19 in Saudi Arabia. *Saudi Med J*. 2021; 42(4): 391- 398.
11. Dong Y, Mo X, Hu Y. Epidemiology of COVID-19 among children in China. *Pediatrics*. 2020; 145(6): e20200702.
12. Leidman E, Duca LM, Omura JD, Proia K, Stephens JW, Sauber-Schatz EK, et al. COVID-19 trends among persons Aged 0-24 years—United States, March 1-December 12, 2020. *MMWR Morb Mortal Wkly Rep*. 2021; 70: 88-94.
13. Paff M, Alexandeu-Abrams D, Muhonen M, Loudon W. Ventriculoperitoneal shunt complications: A review. *Interdiscip Neurosurg*. 2018; S13: 66-70.
14. Chung J, Yu J, Joo HK. Intraabdominal complications secondary to ventriculoperitoneal shunts: CT findings and review of the literature. *AJR Am J Roentgenol*. 2009; 193(5): 1311-1317.
15. Hamid R, Kawsar S. Case Report of a V-P Shunt Dependent Child with Shunt Disconnection and Infection with Extended- Spectrum β -Lactamase-Producing *Klebsiella pneumoniae* (ESBL-KP). *Pediatric Infect Dis*. 2016; 1:18.
16. Hanak BW, Bonow RH, Harris CA, Browd SR. Cerebrospinal Fluid Shunting Complications in Children. *Pediatr Neurosurg*. 2017; 52(6): 381-400.
17. Kast J, Duong D, Nowzari F. Time-related patterns of ventricular shunt failure. *Child's Nerv Syst*. 1994; 10(8): 524-528.

18. Snow RB, Lavyne MH, Fraser RA. Colonic perforation by ventriculo-peritoneal shunts. *Surg Neurol* 1986; 25(2): 173-177.
19. Ghritlaharey RK, Budhwani KS, Shrivastava DK, Srivastava J. Ventriculo-peritoneal shunt complications needing shunt revision in children: A review of 5 years of experience with 48 revisions. *Afr J Paediatr Surg.* 2012; 9(1): 32-39.
20. Ghritlaharey RK. Review of the management of per oral extrusion of ventriculo-peritoneal shunt catheter. *J Clin Diagn Res.* 2016; 10(11): 1-6.
21. Hinojosa J. Complications of peritoneal shunts. In: Di Rocco C, Turgut M, Jallo G, Martinez-Lage J, editors *Complications of CSF Shunting in Hydrocephalus: Prevention, Identification, and Management.* Switzerland: Springer International Publishing; 2015; Pg no: 187-202.
22. Jang HD, Kim MS, Lee NH, Kim SH. Anal extrusion of distal J Korean Neurosurg Soc. 2007; 47: 232-234.
23. Handa R, Kale R, Harjai MM. Unusual complication of ventriculo-peritoneal shunt: Anal extrusion. *Med J Armed Forces India.* 2007; 63(1): 82-84.
24. Birbilis T, Zazos P, Liratzopoulos N. Spontaneous bowel perforation complicating ventriculo-peritoneal shunt: a case report. *Cases J.* 2009; 2: 8251.
25. Guthe SP, Pravin S, Darade P, Velho V. Silent Migration of Ventriculo-peritoneal Shunt per Anus in a Child: Management and Review of Literature. *Asian J Neurosurg.* 2018; 13(2): 446-448.
26. Sharma A, Pandey AK, Diyora B, Shah S, Sayal P. Management of ventriculo-peritoneal shunt protruding through anus. *Indian J Surg.* 2006; 68: 173.
27. Saynhalath R, Alex G, Efun PN, Szmuk P, Zhu H, Sanford EL, et al. Anesthetic complications associated with SARS-CoV-2 in pediatric patients. *Anesth Analg.* 2021; 133(2): 483-490.