

Multistrand Titanium Cable Combined with AO Metacarpal Plate in Treating Acromioclavicular Dislocation

Wang Y, Zhou M, Wu Y, Liu J, Ma Y and Rui Y*

Department of Orthopaedics Surgery, Wuxi No.9 People's Hospital Affiliated to Soochow University, Wuxi, 214000, China

*Corresponding author:

Yongjun Rui,
Department of Orthopaedics Surgery, Wuxi
No.9 People's Hospital Affiliated to Soochow
University, No. 999 Liangxi Road, Wuxi,
214000, Wuxi, China, Tel: +86-13914150156;
E-mail:wswkyryj@163.com

Received: 02 Feb 2022

Accepted: 15 Feb 2022

Published: 19 Feb 2022

J Short Name: ACMCR

Copyright:

©2022 Rui Y. This is an open access article distributed under the terms of the Creative Commons Attribution License, which permits unrestricted use, distribution, and build upon your work non-commercially.

Citation:

Rui Y, Multistrand Titanium Cable Combined with AO Metacarpal Plate in Treating Acromioclavicular Dislocation. *Ann Clin Med Case Rep.* 2022; V8(10): 1-9

Keywords:

Titanium Cable; Acromioclavicular; Coracoclavicular; Surgical operation; Complication

1. Abstract

1.1. Study design: A technique note with case series

1.2. Introduction: As far as we know, no literature is available regarding multistrand titanium cable (MSTC) combined with AO metacarpal plate in treating acromioclavicular (AC) dislocation. Therefore, the current study aimed to evaluate the clinical results of applying such technology in treating AC dislocation.

1.3. Patients and methods: Thirteen patients with AC dislocation that were treated with MSTC combined with AO metacarpal plate in our hospital from June 2016 to April 2017 were enrolled. Postoperatively, radiographs, functional results, and complications were evaluated.

1.4. Results: The 13 patients were followed up for at least 12 months, the average SF-36 for physical domain score in the last follow-up was 57.9 (range, 56.5-60), the average SF-36 for mental domain score was 58.3 (range, 55.5-60.0), the average VAS score for shoulder pain was 0.69 (range, 0.00-2.00), the average DASH score was 4.5 (range, 4-5), the average constant score was 95.2 (range, 92-98), and the average global satisfaction was 8.8 (range, 8-9). The average forward flexion in the 13 patients was 170° (range, 160°-175°), the average lateral elevation was 163° (range, 155°-175°), the average external rotation in adduction was 50° (range, 45°-55°), the average internal rotation in abduction was 71° (range, 66°-75°), and the average strength of abduction was 25pounds (range, 20pounds-28pounds). No imaging complication or surgery-related adverse event occurred.

1.5. Conclusions: MSTC combined with AO metacarpal plate is safe and effective, which is an alternative method to treat AC dislocation. However, its superiority should be further verified in future prospective and randomized controlled trials with large sample size.

2. Introduction

Acromioclavicular (AC) dislocation is a common shoulder injury, which is reported in literature to account for 12% of should injury and 3.2% of systemic bone dislocation [1]. The Rockwood classification is generally adopted for AC dislocation in clinic. Moreover, a consensus has been reached regarding the therapeutic scheme of type I and type II AC dislocation, which is the non-surgical treatment. In comparison, surgical treatment is adopted for type IV, V and VI AC dislocation. However, it remains a source of controversy on whether surgical treatment should be employed for type III patients. A recent systemic review pointed out that, for type III AC dislocation, no significant differences were seen between non-surgical and surgical treatments in shoulder joint function, shoulder pain and the affected upper extremity strength recovery. However, the deformity rate of non-surgical treatment for AC dislocation was markedly higher than that of surgical treatment [2].

Many surgical methods for treating AC dislocation are currently available, including trans-articular hook-plate (HP) and Kirschner wire fixation, as well as extra-coracoclavicular joint repair using metal cable, autologous ligament or LAS artificial ligament [3-11]. According to a recent investigation in Germany, HP and Tight-Rope technology were more feasible [12]. Trans-articular internal

fixation can induce bone erosion, shoulder impact, rotator cuff injury and lead to dysfunction [13,14]. Under physiological conditions, AC joint is a mixed joint. Therefore, it should be taken into consideration in surgery design of how to guarantee firm fixation while maintain the oligodynamic physiological requirement, avoid postoperative shoulder pain and realize non-transarticular internal fixation with favorable reduction. In 2014, Ye et al. [15] had first adopted multistrand titanium cable (MSTC) to treat acute AC dislocation. The authors believed that, coracoclavicular stabilization with MSTC was an effective and safe alternative to other procedures. This procedure provided immediate joint stabilization and allowed early mobilization with satisfying functional recovery. In 2015, Gao YS et al. [16] had used MSTC to treat type V AC dislocation, and compared it with HP. They suggested that MSTC was superior to HP for the treatment of Rockwood type-V AC dislocation both before and after removal of the implant. Hardware removal was of great benefits for functional improvement in patients treated by HP. However, in that study, the authors only enwind the MSTC on the clavicle rather than pass the MSTC through drilling on the clavicle, which is extremely likely to result in MSTC sliding and can not attain the goal of anatomical reconstruction. Therefore, we have modified such surgical procedure on this basis, drilled a hole on the clavicle, and passed the MSTC through the duct. To avoid cutting the clavicular bone, the AO metacarpal plate is also used (Synthes, Oberdorf, Switzerland), which has achieved satisfied clinical efficacy. To our knowledge, this is the first report of MSTC combined with AO metacarpal plate in treating AC dislocation.

This study aimed to describe a novel surgical method in treating AC dislocation, and retrospectively analyze its clinical results.

2.1. Ethics Statement

The study was reviewed and approved by the Regional Committee for Medical and Health Research Ethics. All patients signed an informed consent at follow-up.

2.2. Inclusion and exclusion criteria

This work has been reported in line with the PROCESS criteria[17].

3.1 Inclusion criteria

(1)acute AC-joint instabilities type III or V according to Rockwood's classification system;(2)the injury occurred less than 3 weeks preoperatively[18]; (3)operated within the first three weeks after shoulder injury;(4)with a minimum follow-up of 24 months after surgery;

3.2 Exclusion criteria

(1)combined with coracoid fracture, especially when the fracture lien located in the bottom of coracoid; (2)surgical treatment performed three weeks after ACJ injury(because it has been described that after this period the CC ligaments lack of healing potential[18]

; (3) previous injuries to the respective shoulder.

2.3. Case illustration with surgical technique

3. Case illustration

A 65-year-old women was knocked down by a motorbike 2 h ago, and her right shoulder touched the ground, which led to right shoulder pain and swelling. The patient thus visited the Orthopedics Emergency in our hospital. Physical examination: obvious AC joint tenderness, "key sign" positive, limitation of range (LOM) of right shoulder joint, no paresthesia in right hand and right forearm, right radial arterial pulsation was palpable, and favorable blood circulation was seen in right upper extremity. Right shoulder joint X-ray films revealed right AC dislocation, with the AC joint space of about 9 mm (Fig.1). The patient was given preoperative detumescence (mannitol, 100 ml, intravenous infusion, once/day) and analgesia (celecoxib, 0.2 g, oral administration, once/day) symptomatic treatment. The patient was diagnosed with right AC dislocation (Rockwood III) and was proposed to undergo MSTC combined with AO metacarpal plate treatment.

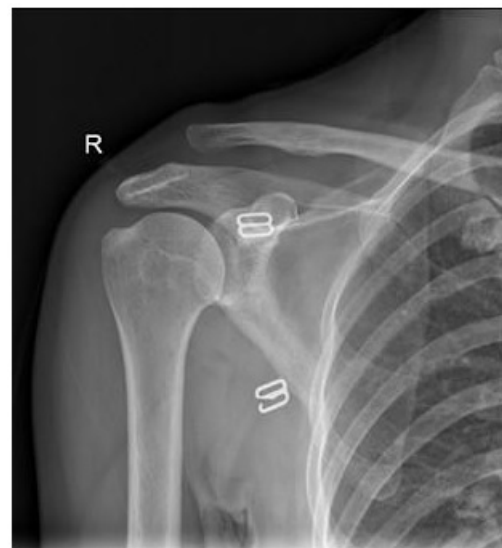

Figure 1: A X-ray in anteroposterior view of a right shoulder with an ACJ injury Rockwood Grade III.

3.1. Surgical technique

All surgeries were completed by an experienced surgeon (FF.L). Cervical plexus anesthesia or general anesthesia was adopted for anesthesia, and patients were in beach chair position. Firstly, the body surface positions of clavicle, acromion and coracoid were labeled (Fig.2A-a), and an arc-shaped surgical incision was made (Fig.2A-b). The arc-shaped flap was opened to expose the coracoid, clavicle and AC joint. Meanwhile, the lateral clavicular segment, AC joint, coracoid and acromion were exposed along the deltoid and trapezius space (Fig.2B-a), and complete rupture of AC joint capsule, AC ligament and coracoclavicular ligament was seen, along with obvious upward dislocation of lateral clavicular segment, and articular disc contusion. The patient was given

removal of obsolete hematoma and broken soft tissue as well as thorough hemostasis. The coniform ligament tunnel location was constructed on the clavicle (Fig.2B-b): 45 mm away from the lateral clavicular border, and the coronal position located in the mid-clavicular line to back. In addition, the trapezoid ligament tunnel location was constructed (Fig.2B-c): 30-35 mm away from the lateral clavicular terminal (such distance should be no less than 15 mm), and the coronal position located in front of the midclavicular line. Afterwards, appropriate metacarpal plate (AO, Synthes) was selected, so that the two holes in the plate could satisfy the above requirement. The 2.0 mm electric drill was used to drill on the clavicle, attention should be paid not to injure the infraclavic-

ular blood vessels and nerves, and periosteal strippers could be used in infraclavicle for protection. Titanium cable (Synthes, West Chester, USA) with the diameter of 1.7 mm was passed along hole b, which came round the coracoid basilar part and passed out of hole c. The titanium cable was tightened using the titanium cable tightener (Fig.2C). The AC joint capsule was sutured with the 2-0# ETHICON tendon stitch (Fig.2B-d), so as to prevent the back-and-forth sliding. The metacarpal screws were screwed into the two holes in the middle of the AO metacarpal plate, so as to prevent plate sliding. Intraoperative X-ray films revealed favorable reduction and fixation. The incision was washed with normal saline, the instruments and gauze were counted, and the incision was sutured layer-by-layer.

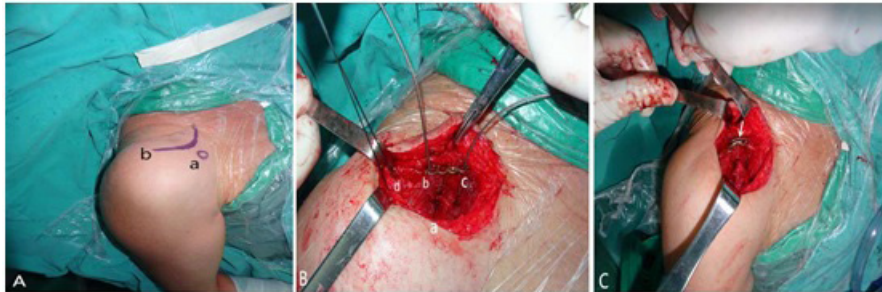


Figure 2: Coracoid body surface markers and incisions during surgery (A). a: coracoid; b: arc-shaped incision; B-a: deltoid and trapezius space; B-b, coniform ligament tunnel location; B-c, trapezoid ligament tunnel location. B-d, repair AC ligament; C, titanium cable tightener (arrow).

3.2. Postoperative treatment

Postoperative antibiotic (cefazolin, 1.0 g, intravenous infusion, twice/day) was administered to prevent infection, along with preventive analgesia (celecoxib, 0.2 g, oral administration, once/day), and detumescence (mannitol, 100 ml, intravenous infusion, once/day). The neck-wrist brace was used for 4 weeks. The functional rehabilitation could be divided into 3 stages: (1) 0-4 weeks after surgery, active movements of hand, wrist and elbow joints were conducted within 24 h after surgery based on the pain tolerance degree of patients. Meanwhile, small-range passive rotatory movements of the shoulder joint were also encouraged. (2) 5-6 weeks after surgery, the neck-wrist brace was removed, and painless shoulder joint range of motion exercises were carried out. (3) After 6 weeks after surgery, painless full-range activities of the affected shoulder were encouraged, along with gradual strengthening exercise. The functional results, imaging results and complications

were recorded in the last follow-up.

4. Series results

Thirteen AC dislocation patients consulted in our hospital and received MSTC combined with AO metacarpal plate surgical treatment from June 2016 to April 2017 (Table 1). All surgeries were completed by an experienced surgeon. All patients were followed for at least 12 months with clinical condition and radiographic images (Fig.3).

The male-to-female ratio among the 13 patients was 8:5, including 3 Roockwood type III patients and 10 Roockwood type V patients. Meanwhile, 8 of them had right AC dislocation, while 5 had left AC dislocation. The average injury-to-surgery interval was 3.6 days (range, 2-7 days), the average time of operation was 1.85 h (range, 1.5-2.5 h), the average intraoperative blood loss was 83.07 ml (range, 50-120 ml), and the average postoperative follow-up period was 15.08 months (range, 12-20 months).

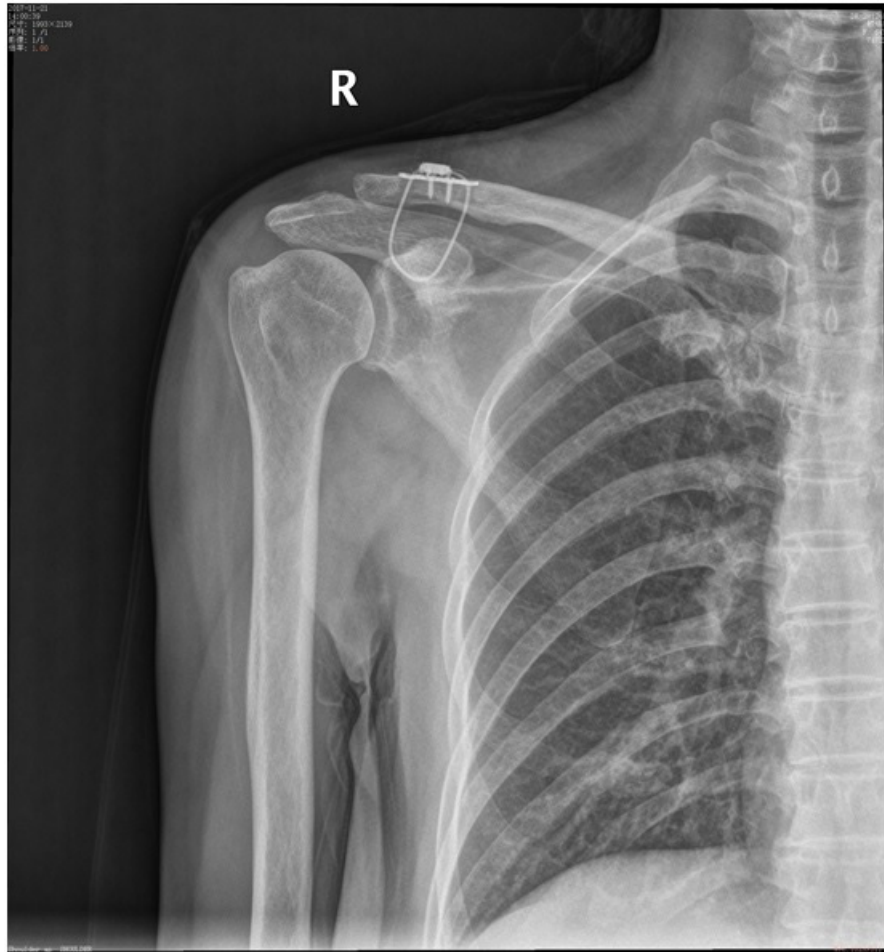

Figure 3: A X-ray in AP view showing a right shoulder in which MSTC combined with AO metacarpal plate was performed.

Table 1: Patient demographics of cohort

Case No.	Sex/Age (years)	Type	Injury side	ISI (day)	OT (hour)	ISI (ml)	OT (months)	Blood loss	Follow-up duration	Complications	
1	F/65	V	R	4	1.5	50	15	None			
2	F/53	III	R	3	2.5	60	12	None			
3	M/56	V	L	3	2.0	75	20	None			
4	F/62	V	L	7	1.5	80	13	None			
5	M/52	V	L	5	2.0	100	16	None			
6	M/47	III	R	3	2.0	80	17	None			
7	M/65	V	R	4	1.8	85	15	None			
8	M/49	V	R	3	1.6	110	12	None			
9	F/61	V	L	3	2.2	120	14	None			
10	M/39	V	L	3			3	2.0	90	18	None
11	M/35	V	R	3	1.8	95	16	None			
12	M/29	V	R	2	1.7	60	15	None			
13	F/33	III	R	4	1.5	75	13	None			

F:female , M : male ; Type means Rockwood type; ISI : Injury-to-Surgery interval
 OT:operation time

4.1. Quality of life (QoL) evaluations

The QoL was assessed by means of [19]:

- the SF36: (1) physical and (2) mental;
- the VAS of the injured shoulder: “0” corresponding to “no pain”and “10” corresponding to “the worst pain imaginable”
- the DASH questionnaire;•the Constant score;
- the “Global Satisfaction” scale (numerical rating scale from 0 to10; being 0, not satisfied with the treatment, and 10, completely-satisfied with the results of the treatment).

Items of the Constant score (range of motion, strength and activ-ity limitations) are also presented separately. In order to be ableto make dichotomous differences between groups; when drawingback items about limitations, “severe” and “moderate” limitationswere grouped into only one category (“yes”). However, for the pur-poses of calculating the Constant score itself, these

items wereconsidered as described by the authors [20] (for exam-ple, sportlimitation: severe, moderate, no).

These results were presented in Table 2, The average SF-36 for physical domain score in the last follow-up was 57.9 (range, 56.5-60), the average SF-36 for mental domain score was 58.3 (range, 55.5-60.0), the average VAS score for shoulder pain was 0.69 (range, 0.00-2.00), the average DASH score was 4.5 (range, 4-5), the average constant score was 95.2 (range, 92-98), and the aver-age global satisfaction was 8.8 (range, 8-9).

The range of motion and strength of the injured shoulder, assessed at the last follow-up visit ,are presented in Table 3 .The average forward flexion in the 13 patients was 170° (range, 160°-175°), the average lateral elevation was 163° (range, 155°-175°), the average external rotation in adduction was 50° (range, 45°-55°), the aver-age internal rotation in abduction was 71° (range, 66°-75°), and the average strength of abduction was 25pounds (range, 20pounds-28pounds) .

Table 2: Quality of life results.

Case No.	SF36*	SF36#	VAS	DASH	Constant score	Global satisfaction
1	56.5	57.5	0.00	5	98	9
2	57.0	58.0	1.00	4	96	9
3	59.0	56.0	0.00	4	95	9
4	58.5	55.5	0.00	4	92	8
5	58.0	59.0	1.00	5	97	9
6	60.0	59.5	1.00	5	95	9
7	57.5	58.5	0.00	5	96	9
8	58.5	59.0	0.00	5	97	9
9	58.0	59.5	2.00	4	95	8
10	57.0	58.5	1.00	5	93	8
11	56.5	58.0	0.00	4	94	9
12	58.5	59.0	2.00	5	96	9
13	57.5	60.0	1.00	4	93	9

*SF36 for physical domain #SF36 for mental domain; VAS: Visual Analogue Scale; DASH: Disability of Arm Shoulder and Hand questionnaire

Table 3: Range of motion and strength of the injured shoulder, assessed at the last follow-up visit

Case No.	FF (°)	LE (°)	ERIA (°)	IRIA (°)	SA(pounds)
1	170	165	50	70	25
2	175	160	45	72	28
3	165	170	55	68	23
4	175	175	45	70	20
5	175	160	50	72	22
6	170	150	50	75	26
7	165	170	45	70	27
8	170	160	55	68	20
9	175	170	55	73	25
10	170	160	45	70	25
11	170	160	50	66	20
12	160	165	55	70	22
13	165	155	50	73	25

FF:Forward flexion;LE:Lateral elevation; ERIA:External rotation in adduction ;IRIA:Internal rotation in abduction; SA: Strength of abduction

4.2. Imaging results

Postoperative follow-up showed no imaging complications in the

13 patients, including internal fixation failure, a second AC dislocation (Fig.4) or coracoclavicular ligament calcification.

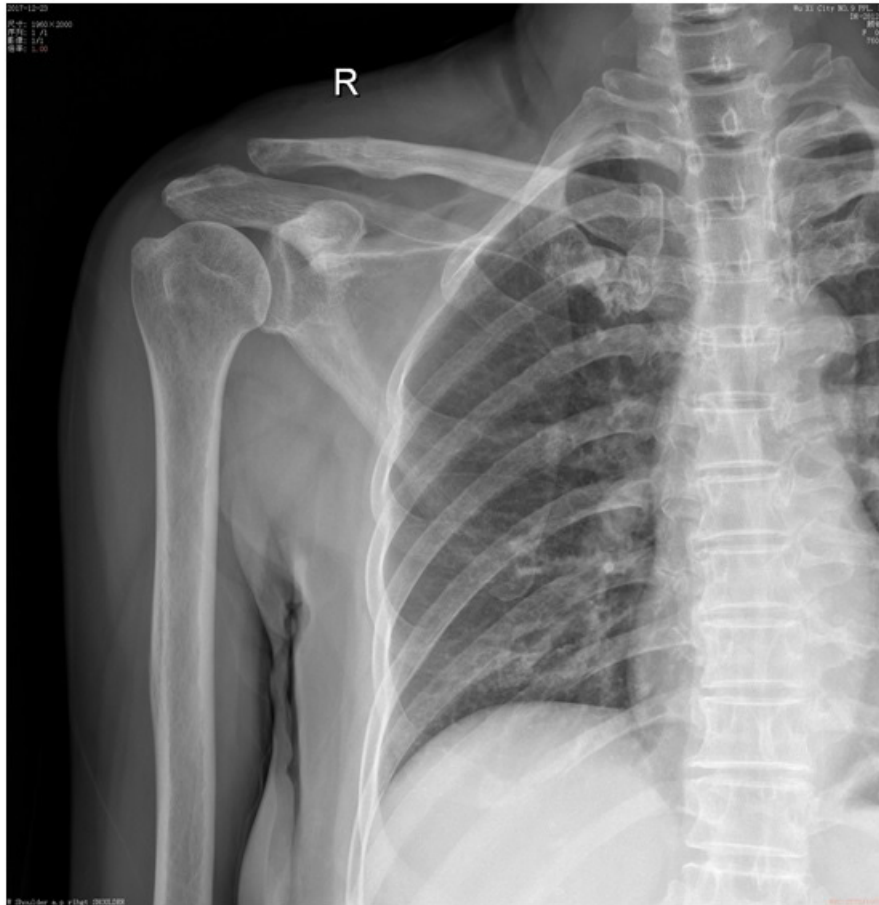

Figure 4: Removal of internal fixation device 6 months after surgery, and no second AC dislocation was seen.

4.3. Adverse events related to treatment and complications

There was no any case of complication such as infection, vascular injury or nerve injury.

5. Discussion

5.1. Surgical procedures for AC dislocation

There are over 150 surgical procedures for AC dislocation, which can be classified into the following 4 categories.

5.1.1. Surgical procedure based on AC joint fixation

In this procedure, the AC joint is mainly fixed with fixation materials. In 1861, Samuel Cooper first used the circumferential metal wiring to fix the AC joint. Thereafter, many fixation method had emerged, and the fixation materials to be used are Kirchner wire, steel wire, Kirschner wire tension band and clavicular hook-plate (HP). Kirchner wire steel tension band is mostly adopted in early treatment, which has the advantages of simple operation, firm fixation and conforming to the mechanical fixation principle. However, the Kirchner wire internal fixation can only fix through the AC joint, which has restricted the micromotion of AC joint and frequently induced shoulder stiffness and pain. Besides, such fixation method can not prevent clavicular rotation, and is susceptible to needle withdrawal, needle rupture and even severe complications such as puncture of thoracic organs. As a steel plate material to fix AC joint, clavicular HP is commonly applied within a certain period of time, which places the hook terminal below the acromion, treats it as the pivot to compress the lateral clavicular terminal through the proximal plate terminal, thus playing a role as reduction and fixation. However, it is associated with the complications such as hook detachment, screw detachment, rupture, rotator cuff injury, collision injury of subacromion, and acromolysis. Besides, for Rockwood type VI injury, the displacement occurs in horizontal position and axial position. The HP has good effects on controlling axial displacement, while poor effects on controlling horizontal and backward displacement [21-25]. Considering the above drawbacks and the improvements of other treatments, HP is decreasingly used in clinic recently.

Such surgical procedure can well relieve AC joint pain, which is more suitable for patients with obsolete AC joint dislocation combined with AC arthritis. Distal clavicular resection will partly affect the weight-bearing function of local AC joint. Therefore, it is more suitable for the aged patients and those not engaged in heavy physical labor or strenuous exercise [26].

5.1.2. Distal clavicular resection

10 mm bone in the distal clavicle is resected in this procedure. Such surgical procedure can well relieve AC joint pain, which is more suitable for patients with obsolete AC joint dislocation combined with AC arthritis. Distal clavicular resection will partly affect the weight-bearing function of local AC joint. Therefore, it is more suitable for the aged patients and those not engaged in heavy physical labor or strenuous exercise [26].

5.1.3. *Muscle-ligament dynamic inversion*

Weaver-Donn surgery includes distal clavicular resection, coracoacromial ligament rotation to replace the coracoclavicular ligament, coracoclavicular suture anchor or Treasureband stitch fixation. Numerous related literature has verified high postoperative patient satisfaction. But the strength of coracoacromial ligament replaced using such method is only 25% of the original coracoclavicular ligament. Consequently, enhanced fixation is frequently required to increase the mechanical stability during ligament healing [27].

5.1.4. *Shoulder arthroscope-assisted technique*

In recent years, the shoulder arthroscopy technology has been developed and popularized, and an increasing number of AC dislocation cases can be surgically treated through arthroscope-assisted operation [28]. Compared with conventional surgical procedure, arthroscopy has unique advantages, such as small trauma, and no interference on muscle tissues such as deltoid and trapezius. Besides, it can more clearly expose the ligament attachment points, allow for accurate positioning using the localizer, and reconstruction surgery is closer to anatomical reconstruction. In addition, it can reduce intraoperative fluoroscopy, protect the patients and medical staff from X-ray radiation, allow for multiple treatments based on minimally-invasive treatment (such as synovium clearance and distal clavicular resection). Typically, the arthroscopy has attained comparable efficacy with the open surgical procedure. Comparatively, arthroscopy is more aesthetics and can be more easily accepted by patients. However, most orthopedists do not like arthroscope-assisted surgery due to the lack of specialist experience.

5.1.5. *Coracoclavicular fixation and the originality of this study*

It is currently believed that the closest surgical method to the biomechanics of AC joint motion is coracoclavicular ligament repair. After coracoclavicular ligament rupture, direct suture repair can hardly satisfy the weight-bearing requirement in practical work and life even after scar healing, which can be attributed to the tension. Over the past 10 years, materials for reconstructing coracoclavicular ligament have been greatly developed, including autologous ligament, LARS, absorbable PDS sling, screw and MSTC. However, no overwhelming material can be defined due to different surgical objectives and methods. Previous studies have indicated that titanium cable is superior to ultra-high molecular weight polyethylene (UHMWPE) or artificial ligament in terms of elasticity and rigidity. High-molecular compound or artificial ligament can achieve favorable early effect in reconstructing coracoclavicular ligament [8], but they are associated with aging and loss of elasticity. Their elasticity and tension will be gradually decreased with time, in comparison, titanium cable is free from such drawback. In the meantime, titanium cable is not subject to the risk of rupture due to hyperplastic osteophyte or sharp border

segmentation in the bone hole border. MSTC has better mechanical properties than traditional titanium cable and steep wire. In a recent study by Ye and colleagues, MSTC was used to pass two drill holes on the clavicle to stabilize the coracoclavicular joint, and the average final evaluation score was 95.3 points [19]. However, the two adjacent holes in the middle of clavicle have added to the risk of iatrogenic fracture [29]. To avoid clavicular bone tunnel segmentation that result in loosening or clavicular fracture, the AO metacarpal plate (Synthes, Oberdorf, Switzerland) is also used, which is the innovation of our study.

Noteworthily, anatomical reconstruction technique is pursued in AC ligament reconstruction in recent years, so that the reconstruction structure is maximally similar to AC joint and coracoclavicular ligament structure, thus attaining favorable therapeutic effect. However, surgery using internal fixation materials for reduction and fixation of AC joint in the ligament anatomical point can not be called anatomical reconstruction technology in principle, since internal fixation materials can not realize vascularization, tissue creeping substitution and become autologous. Instead, it can realize scar healing in the surrounding tissue based on the stable mechanical environment provided by these materials. Either the internal fixation materials or the scar tissues are quite different from the original ligament structure. Therefore, we suggest that it can be referred to as functional reconstruction rather than anatomical reconstruction.

5.2. **Advantages of MSTC combined with AO metacarpal plate**

MSTC combined with AO metacarpal plate in treating AC dislocation has the following advantages: ① the titanium cable is formed through twisting multistrand titanium alloy wires, which has favorable elasticity and toughness as well as high tension after being tightened, and is unlikely to rupture. Besides, it allows for the micromotion between coracoclavicular and AC joints, avoids stress shielding, conforms to the biomechanical requirements, and has the tension resistance and fatigue resistance that can not be observed in single or multiple steel wires. ② Titanium cable has favorable tissue compatibility, with no toxicity or foreign body reaction, which can be left in the body, thus avoiding a second surgery. Even when the patients ask to remove the internal fixation, only a small incision is needed, and no hospitalization is required, which has reduced the therapeutic expenses. ③ It is equipped with the titanium cable tightener, which allows for simple and reliable reduction and operation. Moreover, there is scale of strength of extension in the locking wrench when locking the device, which combined with AO metacarpal plate can avoid titanium cable rupture and segmentation due to excessive stretch, resulting in fracture. ④ It has small injury to soft tissue intraoperatively, requires no exposure of acromion, and has smaller injury than clavicle fixation with HP. ⑤ Titanium cable is used for clavicular-coracoid fixation, which can well control the up-and-down and back-and-

forth displacement of AC joint through adjusting the 2 drill holes in clavicle and the degree of tightness when tightening the cable.

⑥ The internal fixation will not interfere with the AC joint or shoulder joint, which can avoid complications such as shoulder impingement syndrome induced after clavicle HP internal fixation.

⑦ The operation will not involve rotator cuff, and no acromion percussive pain will occur after surgery.

⑧ It can maintain the AC joint stability in the meantime of preserving the rotation activity of clavicle.

⑨ Favorable efficacy can be attained using Endobutton plate and Tightrope to reconstruct the coracoclavicular ligament. Based on this reconstruction principle, the authors have applied titanium cable in reconstructing the coracoclavicular ligament and repairing the AC joint capsule, so as to achieve comparable or even superior therapeutic efficacy over the above methods. Titanium cable is superior to UHMWPE or artificial ligament in terms of elasticity and rigidity. At the same time, it is free from the risk of rupture due to hyperplastic osteophyte or sharp border segmentation in the bone hole border.

5.3. Surgical precautions

Precautions during MSTC combined with AO metacarpal plate in treating AC dislocation: ① the midpoint of the connection between two drills on the clavicle should be dead against the coracoid, any medial or lateral deviation will lead to clavicular rotation displacement after tightening the titanium cable, resulting in unfavorable AC reduction. The clavicular drills should incline forward and downward, so as to avoid injuring the coracoclavicular ligament and prevent excessive forward displacement of clavicle. Besides, two drills on the clavicle should not be too close, which should be 2.0cm in interval. Too large or small interval will lead to segmentation of titanium cable on the clavicle, leading to fixation failure. ② When the titanium cable is passed through the coracoid, attention should be paid not to injure the medial brachial plexus and blood vessels, and it should be close to the coracoid basilar part as far as possible, so as to prevent excessive forward displacement of clavicle and to reduce the risk of stress fracture. ③ Excessive tightening of the titanium cable should be avoided, and the normal coracoclavicular space should be maintained at 11-13 mm. The coracoid to clavicle space should appropriate be one index finger tip in width, as judged intraoperatively or by X-ray films that suggest height recovery of AC joint. Excessive space will lead to segmentation and even AC arthritis.

5.4. Limitations and future study

The current study has some limitations. A small number of patients were included in the research. A control group was not included to demonstrate the advantages of this procedure over other fixation techniques, and further biomechanical tests are req effectiveness of the implant. Long-term follow-up is aluired to verify these needed to assess the complication rates of this surgical technique. Moreover, this study mainly maintains the vertical stability of AC

joint, which is thereby suitable for Rockwood type III or IV, but not suitable for type IV since it is accompanying with distal clavicular retroposition.

6. Conclusions

MSTC combined with AO metacarpal plate is safe and effective, which is an alternative method for treating AC dislocation. However, its superiority should be verified in future prospective and randomized controlled trials with large sample size.

References

1. Fraser-Moodie J A, Shortt N L, Robinson C M. Injuries to the acromioclavicular joint. *Bone & Joint Journal*, 2008; 90(6): 697-707.
2. Korsten K, Gunning A C, Leenen L P H. Operative or conservative treatment in patients with Rockwood type III acromioclavicular dislocation: a systematic review and update of current literature. *International orthopaedics*, 2014; 38(4): 831-838.
3. Takase K, Yamamoto K. Changes in surgical procedures for acromioclavicular joint dislocation over the past 30 years. *Orthopedics*, 2013; 36(10): e1277-e1282.
4. Virtanen K J, Remes V M, Tulikoura I T A, et al. Surgical treatment of Rockwood grade-V acromioclavicular joint dislocations: 50 patients followed for 15–22 years. *Acta orthopaedica*, 2013; 84(2): 191-195.
5. Lizaar A, Sanz-Reig J, Gonzalez-Parreño S. Long-term results of the surgical treatment of type III acromioclavicular dislocations: an update of a previous report. *J Bone Joint Surg Br*, 2011; 93(8): 1088-1092.
6. Verdano M A, Pellegrini A, Zanelli M, et al. Modified Phemister procedure for the surgical treatment of Rockwood types III, IV, V acute acromioclavicular joint dislocation. *Musculoskeletal surgery*, 2012; 96(3): 213-222.
7. Giannotti S, Dell'Osso G, Bugelli G, et al. Surgical treatment of acromioclavicular dislocation with LARS artificial ligament. *European Journal of Orthopaedic Surgery & Traumatology*, 2013; 23(8): 873-876.
8. Wang Y, Zhang J. Acromioclavicular joint reconstruction by coracoid process transfer augmented with hook plate. *Injury*, 2014; 45(6): 949-954.
9. Gille J, Heinrichs G, Unger A, et al. Arthroscopic-assisted hook plate fixation for acromioclavicular joint dislocation. *International orthopaedics*, 2013; 37(1): 77-82.
10. Lu N, Zhu L, Ye T, et al. Evaluation of the coracoclavicular reconstruction using LARS artificial ligament in acute acromioclavicular joint dislocation. *Knee Surgery, Sports Traumatology, Arthroscopy*, 2014; 22(9): 2223-2227.
11. Liu X, Huangfu X, Zhao J. Arthroscopic treatment of acute acromioclavicular joint dislocation by coracoclavicular ligament augmentation. *Knee Surgery, Sports Traumatology, Arthroscopy*, 2015; 23(5): 1460-1466.
12. Balke M, Schneider M M, Shafizadeh S, et al. Current state of treat-

- ment of acute acromioclavicular joint injuries in Germany: is there a difference between specialists and non-specialists? A survey of German trauma and orthopaedic departments. *Knee Surgery, Sports Traumatology, Arthroscopy*, 2015; 23(5): 1447-1452.
13. Eschler A, Gradl G, Gierer P, et al. Hook plate fixation for acromioclavicular joint separations restores coracoclavicular distance more accurately than PDS augmentation, however presents with a high rate of acromial osteolysis. *Archives of orthopaedic and trauma surgery*, 2012; 132(1): 33-39.
 14. Lin H Y, Wong P K, Ho W P, et al. Clavicular hook plate may induce subacromial shoulder impingement and rotator cuff lesion-dynamic sonographic evaluation. *Journal of orthopaedic surgery and research*, 2014; 9(1): 6.
 15. Ye T, Ouyang Y, Chen A. Multistrand titanium cable for the coracoclavicular stabilization of acute acromioclavicular joint dislocation. *Acta Orthop Belg*, 2014; 80: 178-82.
 16. Gao Y S, Zhang Y L, Ai Z S, et al. Transarticular fixation by hook plate versus coracoclavicular stabilization by single multistrand titanium cable for acute Rockwood grade-V acromioclavicular joint dislocation: a case-control study. *BMC musculoskeletal disorders*, 2015; 16(1): 360.
 17. Agha R A, Fowler A J, Rajmohan S, et al. Preferred Reporting of Case Series in Surgery; The PROCESS Guidelines. *International Journal of Surgery*, 2016; 36(Pt A):319.
 18. Weinstein D M, McCann P D, McIlveen S J, et al. Surgical treatment of complete acromioclavicular dislocations. *The American journal of sports medicine*, 1995; 23(3): 324-331.
 19. Natera-Cisneros L, Sarasquete-Reiriz J, Rodriguez-Miralles J. Acute high-grade acromioclavicular joint injuries treatment: Arthroscopic non-rigid coracoclavicular fixation provides better quality of life outcomes than hook plate ORIF. *Orthopaedics & Traumatology: Surgery & Research*, 2016; 102(1): 31-39.
 20. Constant C R, Murley A H. A clinical method of functional assessment of the shoulder. *Clinical orthopaedics and related research*, 1987; (214): 160-164.
 21. Eschler A, Gradl G, Gierer P, et al. Hook plate fixation for acromioclavicular joint separations restores coracoclavicular distance more accurately than PDS augmentation, however presents with a high rate of acromial osteolysis. *Archives of orthopaedic and trauma surgery*, 2012; 132(1): 33-39.
 22. Chiang C L, Yang S W, Tsai M Y, et al. Acromion osteolysis and fracture after hook plate fixation for acromioclavicular joint dislocation: a case report. *Journal of shoulder and elbow surgery*, 2010; 19(4): e13-e15.
 23. Hoffer C E, Karas S G. Transacromial erosion of a locked subacromial hook plate: case report and review of literature. *Journal of shoulder and elbow surgery*, 2010; 19(3): e12-e15.
 24. Ding M, Ni J, Hu J, et al. Rare complication of clavicular hook plate: clavicle fracture at the medial end of the plate. *Journal of shoulder and elbow surgery*, 2011; 20(7): e18-e20.
 25. Di Francesco A, Zoccali C, Colafarina O, et al. The use of hook plate in type III and V acromio-clavicular Rockwood dislocations: clinical and radiological midterm results and MRI evaluation in 42 patients. *Injury*, 2012; 43(2): 147-152.
 26. Mikek M. Long-term shoulder function after type I and II acromioclavicular joint disruption. *The American journal of sports medicine*, 2008; 36(11): 2147-2150.
 27. Thomas K, Litsky A, Jones G, et al. Biomechanical comparison of coracoclavicular reconstructive techniques. *The American journal of sports medicine*, 2011; 39(4): 804-810.
 28. Yoo Y S, Seo Y J, Noh K C, et al. Arthroscopically assisted anatomical coracoclavicular ligament reconstruction using tendon graft. *International orthopaedics*, 2011; 35(7): 1025-1030.
 29. Dumont G D, Russell R D, Knight J R, et al. Impact of tunnels and tenodesis screws on clavicle fracture: a biomechanical study of varying coracoclavicular ligament reconstruction techniques. *Arthroscopy*, 2013; 29(10): 1604-1607.