

Annals of Clinical and Medical Case Reports

Case Report

ISSN 2639-8109 | Volume 8

Ulcerative Colitis with Aseptic Abscesses Controlled by Vedolizumab: A Case Report

Fan Fan^{1,2}, Li Wang^{1,2}, Liming Zhang^{1,2}, Yulan Liu^{1,2} and Ning Chen^{1,2*}

¹Department of Gastroenterology, Peking University People's Hospital, Beijing, China

²Clinical Center of Immune-Mediated Digestive Diseases, Peking University People's Hospital, Beijing, China

*Corresponding author:

Ning Chen,

Department of Gastroenterology, Peking University People's Hospital, Beijing, China, Clinical Center of Immune-Mediated Digestive Diseases, Peking University People's Hospital, Beijing, China,

Tel: (010) 88324785;

E-mail: 13683051579@139.com

Received: 12 Mar 2022

Accepted: 30 Mar 2022

Published: 05 Apr 2022

J Short Name: ACMCR

Copyright:

©2022 Ning Chen. This is an open access article distributed under the terms of the Creative Commons Attribution License, which permits unrestricted use, distribution, and build upon your work non-commercially.

cyclophosphamide, methotrexate, infliximab, adalimumab and

Keywords:

Inflammatory bowel disease; Extraintestinal manifestations; Aseptic abscesses; Vedolizumab

1. Abstract

Introduction: Aseptic abscesses (AAs) are neutrophilic infiltrative lesions that often coincide with systemic inflammatory disorders such as inflammatory bowel diseases (IBD). According to recent literature, medical therapies in IBD with AAs include corticosteroid, immunosuppressants and anti-TNF α biologics.

Report: Herein we reported a patient of ulcerative colitis with AAs and other extraintestinal manifestations treated with vedolizumab that showed a very inspiring outcome.

Discussion: It's the first successful performance of vedolizumab treating moderate-severe ulcerative colitis with aseptic abscesses. This case may provide more therapeutic alternatives for patients with similar conditions in the future and offer hints for future study.

2. Introduction

Aseptic abscesses [AAs] are focal lesions that characterized as inflammatory neutrophils infiltration, negative blood and aspirate pathogen culture, refractory to broad spectrum antibiotics and sensitive to immunosuppressive therapies [1]. Since first described 30 years ago by Andre et al, dozens of cases of aseptic abscesses have been found to associate with Inflammatory bowel diseases [IBD] [2]. AAs are currently accepted as one of the extraintestinal manifestations [EIMs] of IBD, although much rarely presented compared to other types of EIMs involving musculoskeletal systems, skin, eye and hepatobiliary tract [3]. Previous reports showed AA in IBD was successfully treated with corticosteroid, azathioprine,

Citation:

Ning Chen, Ulcerative Colitis with Aseptic Abscesses Controlled by Vedolizumab: A Case Report. *Ann Clin Med Case Rep.* 2022; V8(17): 1-4

surgical modalities [4]. In recent years, a novel monoclonal biologics vedolizumab, was developed to treat IBD which, by targeting at the $\alpha 4\beta 7$ integrin, selectively blocks lymphocytes trafficking to the gastrointestinal tract [5]. Efficacy of vedolizumab to extraintestinal manifestations of IBD is still inconclusive, particularly its efficacy to aseptic abscesses. Herein, we report a case of ulcerative colitis with aseptic abscesses and musculoskeletal manifestations successfully treated with vedolizumab.

3. Case Report

A 33-year-old woman presented with history of ulcerative colitis for 4 years. Mesalazine was effective at the beginning 4 years ago, but gradually became inadequate. Corticosteroid was administered and showed promising effect during induction. However, bloody stool recurred during tapering. By the time she presented, she had fever with body temperature as 38.9°C , abdominal pain and bloody stool 4-6 times per day. She also complained multiple peripheral arthralgia affecting hips, knees, ankles, heels and interphalangeal joints. Physical exam showed tender in left side abdomen. Laboratory tests showed peripheral white cell count $14.6 \times 10^9/\text{L}$, hemoglobin 97g/L , C-reactive protein 80.6mg/L , erythrocyte sedimentation rate 70mm/h , albumin 33.6g/L . Liver and renal function and electrolyte tests were unremarkable. We conducted comprehensive infectious pathogen screening tests including blood culture for bacteria and fungi, fungal $1,3\text{-}\beta\text{-D-glucan}$ and galactomannan test, test for *Clostridium difficile* toxin, microscopic pathogen detection for stool smear, T-cell spot test for tuberculosis, nucleic acid test for CMV and EBV that were all negative. A contrast-enhanced CT scan was performed which showed diffused thickening of left-

side colon wall, multiple low enhanced lesions in liver and kidneys and multiple newly appearing lymphadenopathies in mediastinal, mesenteric and para-abdominal aortic areas with some particularly enlarged abdominal lymph nodes that were up to 2-3cm diameters with central liquefactive necrosis [Figure 2B]. Those image results were confirmed by enhanced MR scan [Figure 2A]. Colonoscopy demonstrated active ulcerative colitis that affected from the transverse colon near the hepatic flexure to the descending colon [Figure 1A, 1B]. She was diagnosed as ulcerative colitis. Pathological nature of the enlarged abdominal lymphadenopathies and hepatic and renal lesions were considered including multi-organ infectious lesions, which is reasonable considering her immunocompromised status due to colitis and past history of using corticosteroid, and lymphoma which have been reported repeatedly in patients of inflammatory bowel disease with lymphadenopathy. She was administered with broad spectrum antibiotics for 3 weeks (Ertapenem 1g every day for a week, Cefoperazone/Sulbactam 3g every 8 hours with Ornidazole 0.5g every 12 hours for a week and levofloxacin 0.4g every day with Ornidazole 0.5g every 12 hours for a week). Her peripheral white cell count was moderately improved. However, activity of bowel disease and other manifestations showed much less alleviation. PET-CT scan was conducted that showed no indication of lymphoma. We also performed endoscopic ultraso-

nography with fine needle aspiration [EUS-FNA]. Results of EUS coincided with CT and MR scan and FNA acquired 2ml of purulent fluid which was further sent to bacteria, fungi and tuberculosis cultures, Next Generation Sequencing [NGS] for pathogens, pathological examination and cytological smears [Figure 3]. Evidence of infectious pathogen was negative and pathological exam demonstrated necrotic tissue with neutrophils infiltration. Hip joints MR scan was also performed with experienced rheumatologist's evaluation that confirmed polyarthritis. We finally diagnosed her as ulcerative colitis (chronic relapse, pancolitis, moderate to severe activity), aseptic abscesses (mesenteric lymph nodes, liver and kidneys), musculoskeletal manifestation (peripheral arthropathy) and recommended vedolizumab for her. We then witnessed a dramatic remission of her intestinal and articular symptoms and improvement of her lymphatic enlargement, hepatic and renal lesions that were confirmed by colonoscopy and MR scan at the time of 4-month follow-up [Figure 1C, 1D, 2C and 2D]. Her hemoglobin and albumin levels gradually recovered to normal and inflammatory markers such as CRP decreased accordingly. Till the time this report written, it has been 9 months since vedolizumab therapy began, she came back to hospital periodically for continuous treatment and surveillance, and there's no sign of any sort of relapse.

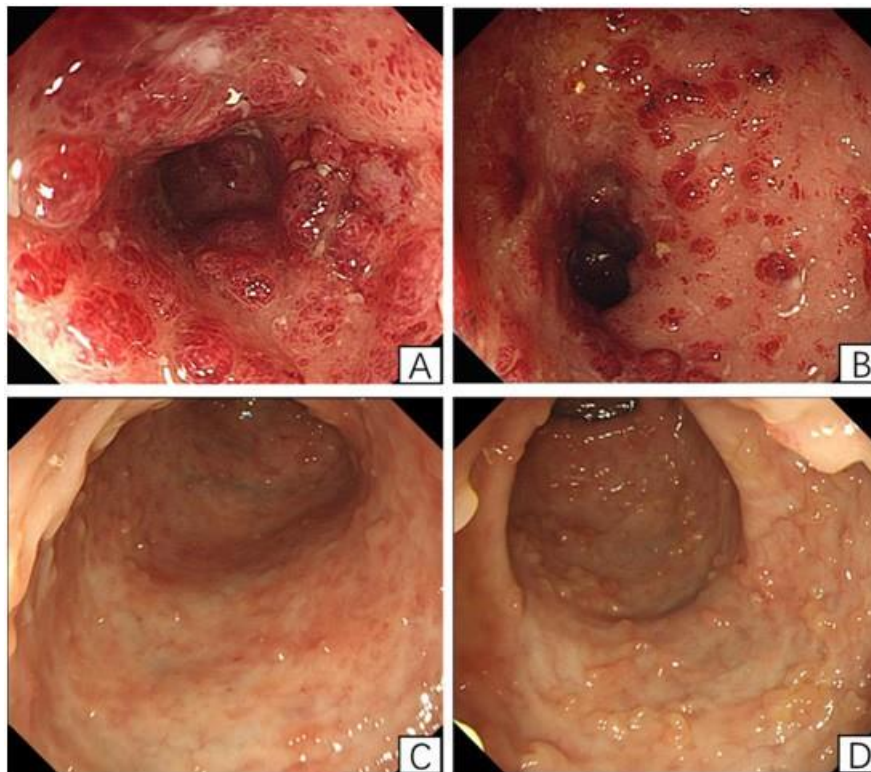


Figure 1: Colonoscopy images of transverse colon and descending colon before and after 4 months of treatment.

Colonoscopy showed friable mucosa, diffused mucosal congestion and edema with flaky ulcers and erosions covered with mucopurulent secretions and lack of vascular pattern in the descending colon (A) and transverse colon (B) at the time of admission and recovered mucosa with nascent granulation tissue and inflammatory polyps in the descending colon (C) and transverse colon (D) 4 months after treated with vedolizumab.

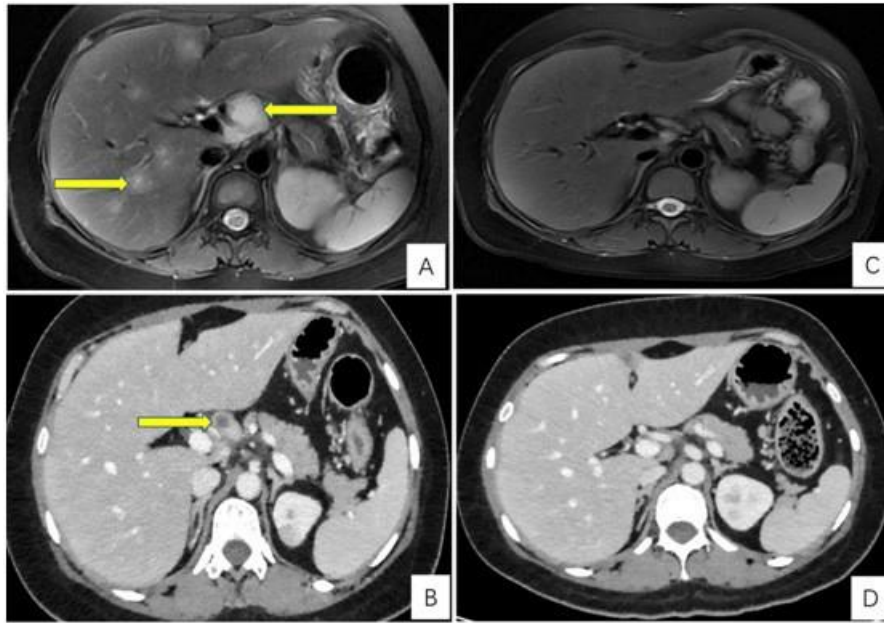


Figure 2: Abdominal radiological images demonstrating hepatic and renal lesions and aseptic abscesses before and after 4 months of treatment. MRI (A, C) and CT (B, D) scan of upper-abdomen showed multiple lesions in liver and kidneys (green arrows) and enlarged abdominal lymph node with central liquefactive necrosis (yellow arrows) at the time of admission (A, B). After treated with vedolizumab, the lesions decreased in sizes (B, D).

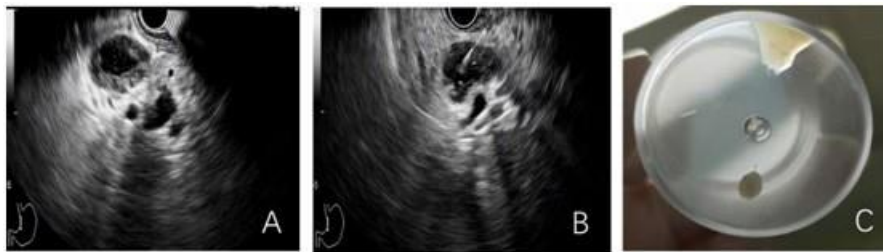

Figure 3: Endoscopic ultrasonography and fine needle aspiration (EUS-FNA) of the enlarged and necrotic lymph nodes.

EUS demonstrated abdominal enlarged lymph nodes with central liquefactive necrosis (A). Fine needle aspiration was performed and 2ml of purulent fluid was acquired (B and C).

4. Discussion

To our knowledge, this is the first case of ulcerative colitis with aseptic abscesses treated with vedolizumab that showed a promising result during at least 9 months follow-up. Aseptic abscesses were first described in 1995 by Andre et al. in patients with abscesses that could not be explained by infection because of unresponsiveness to antibiotics and sensitivity to corticosteroid [2]. It often associates with systemic inflammatory conditions, mostly IBD as one of extraintestinal manifestation [6, 7]. Similar to neutrophilic dermatosis such as Pyoderma Gangrenosum and Sweet's Syndrome which are two types of more often seen dermatological manifestations of IBD, histopathological characteristics of AA is sterile predominant neutrophils infiltration of the deep tissues [6]. There is currently no diagnostic criterion for AA. However, Andre and colleagues came up with a set of common characteristics base on case series for clinicians to evaluate AA: (1) deep abscesses with neutrophilic features; (2) negative findings of causative infectious pathogen from serological tests and cultures of blood and aspiration sample; (3) failure of broad-spectrum antibiotics;

(4) clinical improvement on corticosteroid therapy with or without additional immunosuppressant which is confirmed by radiologic evidence [3]. According to the latest literature review by Yamaguchi. Y and teammates, 43 patients of IBD-associated AA were identified in MEDLINE from 1994 to 2020. Patients may present with fever, abdominal pain, weight loss and diarrhea. Lesions may be located at spleen, liver, lymph nodes, muscles, kidneys, sternum and other locations in very rare cases. Patients may coincide with other EIM of IBD such as arthritis, myalgia, neutrophilic dermatosis, aphthous ulcer, panniculitis and polyneuropathy. Several treatments had been reported including corticosteroids which is most often mentioned, cyclophosphamide, azathioprine, methotrexate, granulocytapheresis, adalimumab, infliximab and surgical procedures such as splenectomy, incision and drainage, laparoscopic biopsy of lymph nodes [1]. In this case, we regarded this patient as IBD-associated AAs according to results of pathogen tests, histopathological findings and therapeutic effect of broad-spectrum antibiotics. However, other differential diagnoses such as opportunistic infection, lymphoma and tuberculosis infection couldn't

be excluded. Thus, among several therapeutic options including corticosteroid, anti-TNF biologics, and anti-Integrin biologics, we deemed vedolizumab as the optimal choice for her from the perspective of safety because of its intestinal selectivity. Outcome of this treatment was inspiring for not only remission of colonic mucosal inflammation but also alleviation of AAs and arthralgias. Inflammatory bowel disease is not limited to the digestive tract and is regarded as a systemic immune disorder with nearly one half of patients experiencing extraintestinal manifestations which involve multiple organs and systems including musculoskeletal system, skin, ocular organ and hepatobiliary tract and others [8]. The pathophysiological mechanism of EIMs is unclear with several hypotheses. Either they could be the result of intestinal immune activation with inflammatory cells and cytokines subsequently trafficking or diffusing to extraintestinal target organs, or they, together with gastrointestinal tract, could be simultaneously involved by systemic immune disturbance [3]. Vedolizumab is a gut-selective antibody to $\alpha 4\beta 7$ integrin for treatment of moderate-severe IBD. Studies have shown long-term effectiveness and a favorable safety profile of vedolizumab with low incidence rates of serious infections and malignancies at least partially due to its selectivity [9, 10]. It is uncertain whether a gut-selective action is suitable for controlling EIMs such as aseptic abscesses and musculoskeletal manifestations. In a systemic review worked by Hanzel. J and team, vedolizumab may be effective for musculoskeletal EIMs associated with disease activity [3]. There were case reports suggesting that vedolizumab could be effective for pyoderma gangrenosum according to Groudan K. et al., Fleisher M. et al. and Shibuya T. et al. [11, 12, 13]. However, there were no randomized controlled trials that specifically study the efficacy of vedolizumab for IBD related EIMs especially aseptic abscesses and arthropathy, and evidence from different observational studies are of modest quality. Thus, large-scale well-designed prospective studies are needed in the future in order to definitively answer such questions.

References

1. Yamaguchi Y, Nakagawa M, Nakagawa S. Rapidly Progressing Aseptic Abscesses in a Patient with Ulcerative Colitis. *Intern Med.* 2021; 60(5): 725-730.
2. Sakharpe AK, Sakharpe AK, Mirmanesh M. A case and review of aseptic liver abscess in Crohn's disease. *Int J Colorectal Dis.* 2016; 31(3): 787-788.
3. Hanzel J, Ma C, Castele NV, Khanna R, Jairath V, Feagan BG. Vedolizumab and Extraintestinal Manifestations in Inflammatory Bowel Disease [published correction appears in *Drugs*. 2021 Aug 28;:]. *Drugs.* 2021; 81(3): 333-347.
4. Bollegala N, Khan R, Scaffidi MA. Aseptic Abscesses and Inflammatory Bowel Disease: Two Cases and Review of Literature. *Can J Gastroenterol Hepatol.* 2017; 2017: 5124354.
5. Feagan BG, Sandborn WJ, Colombel JF. Incidence of Arthritis/Arthralgia in Inflammatory Bowel Disease with Long-term Vedolizumab Treatment: Post Hoc Analyses of the GEMINI Trials. *J Crohns Colitis.* 2019; 13(1): 50-57.
6. Fillman H, Riquelme P, Sullivan PD, Mansoor AM. Aseptic abscess syndrome. *BMJ Case Rep.* 2020; 13(10): e236437.
7. Antonelli E, Bassotti G, Tramontana M. Dermatological Manifestations in Inflammatory Bowel Diseases. *J Clin Med.* 2021; 10(2): 364.
8. Vavricka SR, Schoepfer A, Scharl M, Lakatos PL, Navarini A, Rogler G. Extraintestinal Manifestations of Inflammatory Bowel Disease. *Inflamm Bowel Dis.* 2015; 21(8): 1982-1992.
9. Loftus EV Jr, Colombel JF, Feagan BG. Long-term Efficacy of Vedolizumab for Ulcerative Colitis. *J Crohns Colitis.* 2017; 11(4): 400-411.
10. Colombel JF, Sands BE, Rutgeerts P. The safety of vedolizumab for ulcerative colitis and Crohn's disease. *Gut.* 2017; 66(5): 839-851.
11. Shibuya T, Haga K, Saeki M. Pyoderma gangrenosum in an ulcerative colitis patient during treatment with vedolizumab responded favorably to adsorptive granulocyte and monocyte apheresis. *J Clin Apher.* 2020; 35(5): 488-492.
12. Groudan K, Gupta K, Singhanian R. Vedolizumab (Entyvio®) for the Treatment of Pyoderma Gangrenosum in a Crohn's Disease Patient. *Cureus.* 2021; 13(1): e12582.
13. Fleisher M, Marsal J, Lee SD. Effects of Vedolizumab Therapy on Extraintestinal Manifestations in Inflammatory Bowel Disease. *Dig Dis Sci.* 2018; 63(4): 825-833.