

Diagnosis of Cavernous Sinus Hemangioma by [99mTc]Tc- RBC Scintigraphy

Ortiz SAG* and del Moral FJH

Nuclear Medicine Service, Puerta de Hierro Majadahonda University Hospital, Madrid, Spain

*Corresponding author:

Stefanía Aida Guzmán Ortiz,
Nuclear Medicine Service, Puerta de Hierro
Majadahonda University Hospital, Madrid, Spain,
Tel: 639535735; E-mail: estefany--go@hotmail.com

Received: 28 Aug 2022

Accepted: 07 Sep 2022

Published: 12 Sep 2022

J Short Name: ACMCR

Copyright:

©2022 Ortiz ASG. This is an open access article distributed under the terms of the Creative Commons Attribution License, which permits unrestricted use, distribution, and build upon your work non-commercially

Citation:

Ortiz SAG, Diagnosis of Cavernous Sinus Hemangioma by [99mTc]Tc- RBC Scintigraphy. Ann Clin Med Case Rep. 2022; V9(13): 1-3

Keywords:

Hemangiomas; Meningiomas; Extracerebral

1. Abstract

Preoperative diagnosis of cavernous hemangiomas (HC) is generally difficult because they are rare lesions that are misdiagnosed as meningiomas on Computed Tomography (CT) and Magnetic Resonance Imaging (MRI), being essential their differential diagnosis prior to biopsy or surgery, because extracerebral cavernous sinus HC is often complicated by incomplete excision and/or hemorrhage with a high morbidity and mortality rate. We present the case of a 51-year-old male with a history of tinnitus and vertigo. He underwent an MRI which showed a 0.8cm right cavernous lesion compatible with meningioma. In view of the findings of right parasellar meningioma, it was decided to follow up the lesion with MRI, which remained stable for ten years. However, in the last control study there was evidence of minimal growth of the lesion, currently measuring 1cm, with a hypointense signal in T1 and hyperintense in T2 with intense enhancement after gadolinium administration. Neither the dural tail seen in the baseline study nor the mass effect was clearly seen, so the differential diagnosis of hemangioma vs. meningioma was considered. A brain scintigraphy with autologous red blood cells labeled with Tc-99m ([99mTc] Tc-RBC) was performed, which showed a right parasellar focal deposit in the early phase that progressively increased in the late phase of the study, showing a characteristic pattern of hemangioma. Given the significant morbidity and mortality encountered in the surgery of patients with cavernous sinus hemangiomas, the patient is treated conservatively. In conclusion, the prospective diagnosis by combined use of MRI and brain scintigraphy with [99mTc]Tc-RBC is potentially beneficial for the differential diagnosis between hemangioma and cavernous sinus meningioma.

2. Introduction

Extracerebral intracranial cavernous hemangiomas (CH) involving the cavernous sinus account for less than 1% of all parasellar masses. Their preoperative diagnosis is generally difficult because they are rare lesions that are misdiagnosed as meningiomas (most frequent lesion in the cavernous sinus) on computed tomography (CT) and magnetic resonance imaging (MRI), being essential their differential diagnosis prior to biopsy or surgery, because extracerebral cavernous sinus CH is often complicated by incomplete excision and/or hemorrhage with a high morbidity and mortality rate [1].

Brain scintigraphy with autologous red blood cells labeled with Tc-99m ([99mTc]Tc- RBC) (an intravascular radiotracer) has been widely used in nuclear medicine mainly for the evaluation of the cardiovascular system, detection of gastrointestinal bleeding and has also been found to be specific for the diagnosis of CH of the liver, thus, due to this high specificity it has been used for the diagnosis of hemangiomas in other locations such as intracranial [2].

The pattern of absence of vascularization of the lesion in the vascular phase that increases in intensity with time suggests hemangioma, so when this lesion is suspected, a late phase should be performed to demonstrate the true blood content of the lesion. This finding is explained by the low perfusion and large blood volume of cavernous hemangiomas [3].

3. Case Presentation

A 51-year-old male with a history of tinnitus and vertigo. MRI showed a 0.8cm right cavernous lesion, hypointense in T1 sequence, hyperintense in T2 sequence and with intense enhance-

ment after gadolinium administration, which was associated with a dural tail compatible with the diagnosis of meningioma. In view of the findings of right parasellar meningioma, it was decided to follow up the lesion with MRI, which remained stable for ten years. However, in the last control study there was evidence of minimal growth of the lesion, currently measuring 1cm, with a hypointense signal in T1 and hyperintense in T2 with intense enhancement after gadolinium administration. Neither the dural tail seen in the baseline study nor the mass effect was clearly visible, so the differential diagnosis of hemangioma vs. meningioma was considered (Figure 1).

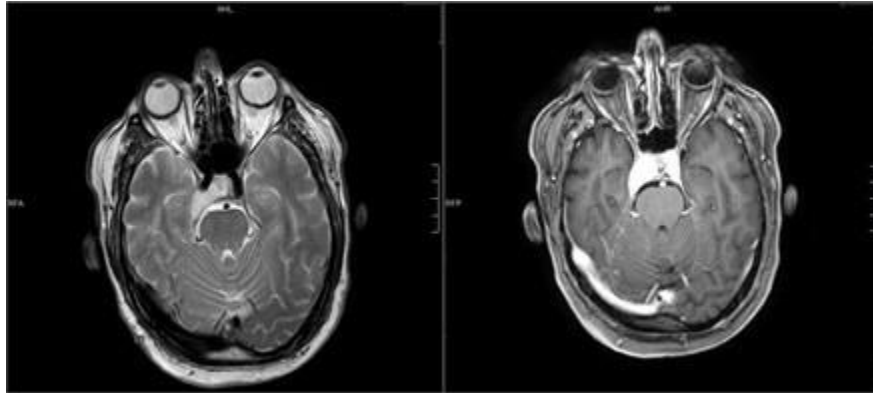


Figure 1: MRI showed a lesion with well-defined borders that does not alter the vascular contour, does not associate dural tail and presents a very marked hyperintense signal in T2 that after administering gadolinium has an intense enhancement.

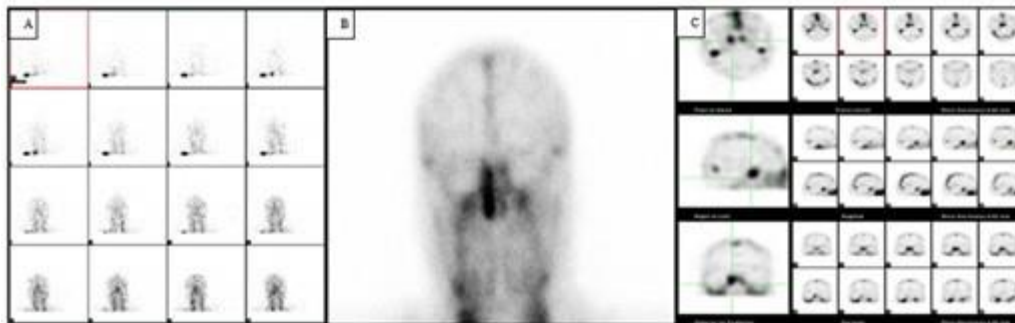


Figure 2: Brain scintigraphy with $[^{99m}\text{Tc}]\text{Tc-RBC}$. Angiogram phase (A) shows that the radiotracer was distributed in the brain in a physiological manner without showing areas of increased vascularization. Early phase (B) shows focal deposition of the right parasellar radiotracer. Late phase (C) shows SPECT images obtained at 2 hours with an intense accumulation of radiotracer in the right parasellar region compared to the left parasellar region, indicating the existence of a lesion with high blood content.

4. Discussion

Given the findings of a lesion with hypointense signal in T1 sequence and marked hyperintense in T2 and intense enhancement after administering gadolinium that does not compress the internal carotid lumen in the MRI combined with an increase in radiotracer deposition in the late phases of the $[^{99m}\text{Tc}]\text{Tc-RBC}$ scan, the patient was diagnosed with CH. Given the significant morbidity and mortality found in the surgery of patients with cavernous sinus hemangiomas, the patient is treated conservatively and therefore, there is no histological confirmation of the nature of this lesion.

The differential diagnosis of hemangioma with meningioma with MRI is characterized by the fact that the hyperintense signal in T2

It was decided to perform a brain scintigraphy with autologous red blood cells labeled with $\text{Tc-}^{99\text{m}}$ ($[^{99\text{m}}\text{Tc}]\text{Tc-RBC}$) and dynamic imaging was performed immediately after administration of the radiotracer (angiogram phase), a static and early image at 30 minutes (early phase) and a SPECT (single photon emission computed tomography) at 2 hours after radiotracer administration (late phase) showing that the radiotracer in the angiogram phase was distributed in the brain in a physiological manner without showing areas of increased vascularization, In the early phase, a right parasellar focal deposit was observed, which progressively increased in the late phase of the study, showing a characteristic hemangioma pattern (Figure 2).

is more intense in hemangioma than in meningioma, moreover, hemangioma does not produce mass effect nor does it associate dural tail, while meningioma produces mass effect compressing the adjacent vascular structures and generally associates dural tail. On $[^{99\text{m}}\text{Tc}]\text{Tc-RBC}$ scintigraphy, hemangioma shows a progressive increase of radiotracer in the lesion that is better evidenced in the late phases, whereas meningioma does not show uptake but a photopenic area consistent with replacement or compression of the cavernous sinus affected by the tumor [1].

5. Conclusion

The prospective diagnosis by combined use of MRI and brain scintigraphy with $[^{99\text{m}}\text{Tc}]\text{Tc-RBC}$ of the brain is potentially beneficial

for the differential diagnosis between hemangioma and cavernous sinus meningioma.

References

1. Salanitri GC, Stuckey SL, Murphy M. Extracerebral cavernous hemangioma of the cavernous sinus: diagnosis with MR imaging and labeled red cell blood pool scintigraphy. *AJNR Am J Neuroradiol.* 2004; 25(2): 280-4.
2. Gdal-On M, Gelfand YA, Israel O. Tc-99 m labeled red blood cells scintigraphy: a diagnostic method for orbital cavernous hemangioma. *Eur J Ophthalmol.* 1999; 9(2): 125-9.
3. Hardoff R, Gips S, Front A. Imaging patterns of vascular lesions of the head and neck demonstrated by Tc-99m labeled red blood cells. *Clin Nucl Med.* 1992; 17(4): 288-91.