

A Rare Case Report Of Hyperparathyroidism With Multiple Osteolytic Lesions Misdiagnosed As Multiple Myeloma

Zailin Yang ^{1*}, Bingling Guo^{1*}, Lisheng Liu^{2#}, Yu Peng^{1#} and Yao Liu^{1#}

¹Department of Hematology-Oncology, Chongqing Key Laboratory of Translational Research for Cancer Metastasis and Individualized Treatment, Chongqing University Cancer Hospital, Chongqing, 400030, China

²Nucler Medicine Department, Chongqing Key Laboratory of Translational Research for Cancer Metastasis and Individualized Treatment, Chongqing University Cancer Hospital, Chongqing, 400030, China

* These authors' contribution is equally to this work.

#Corresponding author:

Yao Liu, Yu Peng, Lisheng Liu,

Department of Hematology-Oncology, Nucler Medicine Department, Chongqing Key Laboratory of Translational Research for Cancer Metastasis and Individualized Treatment, Chongqing University Cancer Hospital, Chongqing, 400030, China

Received Date: 26 February 2024

Accepted Date: 11 March 2024

Published Date: 16 March 2024

Citation:

Yao Liu, Yu Peng and Lisheng Liu. A Rare Case Report Of Hyperparathyroidism With Multiple Osteolytic Lesions Misdiagnosed As Multiple Myeloma. *Annals of Clinical and Medical Case Reports* 2024.

1. Abstract

Hyperparathyroidism with diffuse bone lesions is relatively rare, typically manifesting with symptoms such as bone pain or pathologic fractures. Due to the lack of understanding of this disease, these extensive lytic lesions are often misdiagnosed as primary or metastatic cancer and referred to Oncologists. We report a case of hyperparathyroidism (HPT) with imaging manifestations similar to those characteristic of multiple myeloma (MM), which was misdiagnosed as MM. Our patient at presented with the hospital with a recurrent cough, sputum, and sternal pain. Computed tomography (CT) scan and magnetic resonance imaging (MRI) suggested that this patient had generalized osteolytic destruction and multiple bone marrow lesions. Furthermore, the serum 25-hydroxy-vitamin D [25(OH)D] levels was significantly reduced, while the serum parathyroid hormone (PTH)

levels were significantly elevated. In this case, the patient's diagnosis was based on her medical history and laboratory test results. HPT with extensive bone lesions, exhibiting imaging manifestations similar to those of MM, is relatively rare. It is highly challenging to accurately diagnose as HPT. This indicates that clinicians should consider not only MM but also HPT with bone disease in patients exhibiting characteristic MM imaging feature. This perspective offers a novel diagnostic approach for the clinical practice.

2. Keywords:

Hyperparathyroidism, multiple osteolytic lesions, multiple myeloma, imaging

3. Introduction

Hyperparathyroidism (HPT) is an endocrine disorder with inappropriately elevated levels of parathyroid hormone (PTH) activity. Pathologic fractures complicated by HPT is an established clinical manifestation, as bone is a major target organ of PTH [1]. The incidence of pathologic fractures associated with HPT accounts for 16.4% of patients with HPT [2,3]. There is a large amount of the previous literature on the diagnosis and treatment of HPT. However, limited attention has been given to the diagnosis and treatment of HPT complicated with pathologic fractures pathologic fractures have been reported. The diagnosis and treatment of this disease remain challenging in the clinical. We are presenting a case report about a 65-year-old female patient who presented with pathological fracture associated with multiple osteolytic lesions, which was highly prone to being misdiagnosed as multiple myeloma (MM) through imaging, and ultimately diagnosed as HPT.

4. Case report

A 65-year-old woman patient presented to hospital with recurrent cough, sputum, and sternal pain. A full blood count showed red blood cell of $2.83 \times 10^{12}/L$, hemoglobin concentration of 84 g/L, white blood cells count of $3.71 \times 10^9/L$, and platelet count of $135 \times 10^9/L$. There was significantly elevated serum urea (12.95 mmol/L), serum creatinine (258.20 $\mu\text{mol}/L$) and serum cystatin C (3.56 mg/L), and mildly reduced serum calcium level (1.36 mmol/L). Serum albumin was 39 g/L, while serum globulin was 28.2 g/L. Serum β_2 -microglobulin level (13.19 mg/L) and serum lactate dehydrogenase level (302.0 U/L) was elevated. Computed Tomography CT scan of the cranial and chest suggested generalized osteolytic destruction with pathologic fracture of multiple ribs (Figure 1).

Annals of Clinical and Medical Case Reports

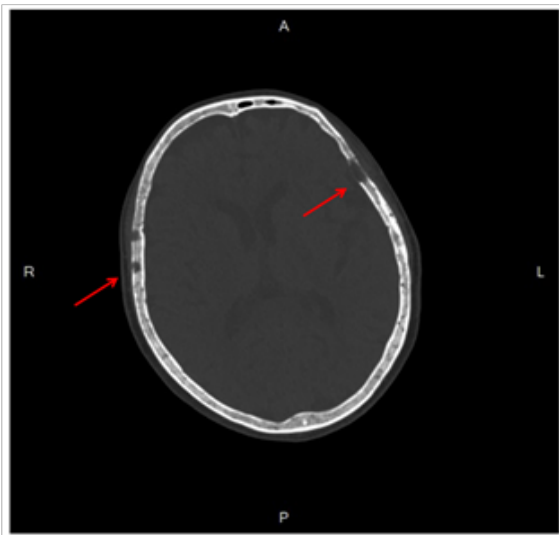


Figure 1: Computed Tomography (CT) scan of the patient's skull revealed multiple punched-out appearance (arrows).

MRI examination of the spine revealed multiple bone marrow lesions exhibiting nodular and patchy enhancement on contrast-enhanced T1-weighted (Figure 2).

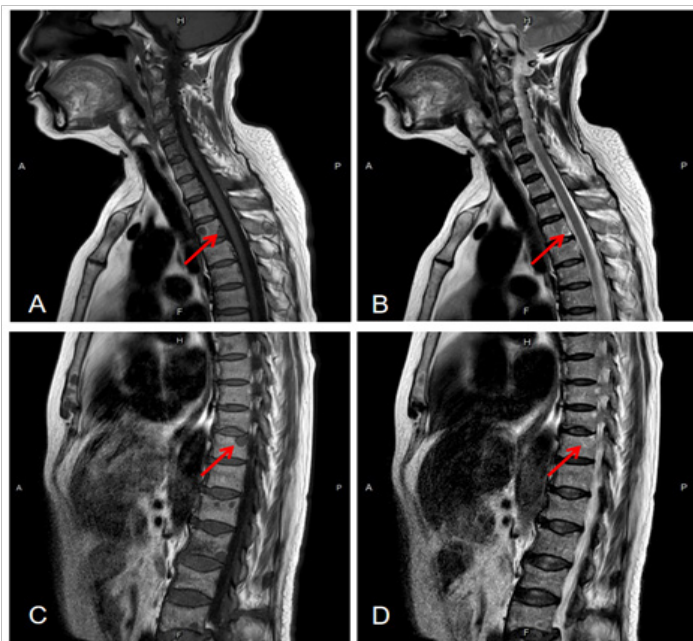


Figure 2: Spinal magnetic resonance imaging (MRI) examination showing multiple vertebral lesions (arrows), low signal on T1-weighted images (A, C) and high signal on T2-weighted images (B, D)

Whole-body positron emission tomography-computed tomography (PET-CT) demonstrated multiple foci with moderately increased FDG uptake involving the skull, bilateral humerus, clavicle, scapula, ribs, spine, pelvic bones, bilateral femur and soft tissue of the left sciatic tubercle (Figure

3). Heterogeneous FDG uptake was observed in multiple bone lesions, including pelvic bones (SUVmax=2.3) and soft tissue of the left sciatic tubercle (SUVmax=2.8). Combined with the patient's results of CT, MRI and PET-CT indicated that the patient's imaging manifestations similar to those characteristics of MM.

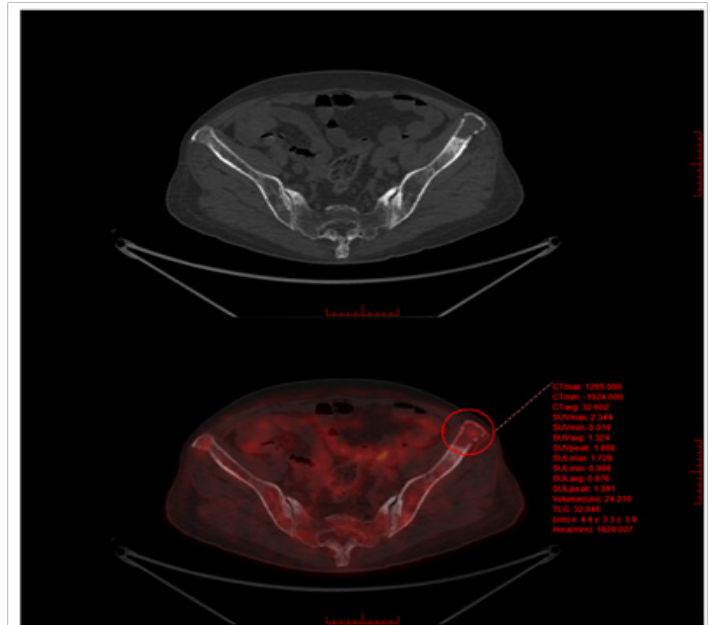


Figure 3: Positron emission tomography-computed tomography (PET-CT) demonstrated moderately increased FDG uptake in the osteolytic lesion of left ilium (SUVmax = 2.3).

Further diagnostic investigations were conducted to identify the cause of multiple osteolytic lesions. The serum kappa light chain level measured 2.7 g/L, and the serum lambda light chain level was 0.9 mg/L, with a Kappa:Lambda ratio of 3:1. However, serum protein electrophoresis, serum immunofixation electrophoresis, and Bence-Jones protein showed normal. Bone marrow aspirate indicated normal proportions of plasma cells, whereas the bone marrow biopsy did not reveal plasma cell aggregates or plasma cells with abnormal immunophenotype. Subsequent flow cytometry of bone marrow did not detect plasma cells with light chain restriction. Additionally, fluorescence in situ hybridization (FISH) analysis revealed no characteristic cytogenetic alterations of MM were detected in the patient. Interestingly, the patient had a past history of hypertension, diabetes mellitus, and hyperthyroidism, and was currently undergoing treatment with felodipine, metformin, glimepiride, and levothyroxine sodium tablets (Euthyrox®). The major adverse effects of levothyroxine sodium therapy include muscle wasting, excess bone loss or osteoporosis [4,5]. Furthermore, the serum 25(OH)D level was significantly reduced at 17.9 ng/ml, while the serum PTH level was significantly elevated at 139.1 pg/ml. The serum total thyroxine (TT4), serum total triiodothyronine (FT3), and serum thyroid stimulating hormone (TSH) levels were normal. Therefore, a diagnosis of HPT with bone lesions was established based on the patient's medication history

Annals of Clinical and Medical Case Reports

hypocalcemia and decreased levels of 25(OH)D.

5. Discussion

The differential diagnosis for this patient should include metastasis, MM, and HPT, all of which may also present with multiple osteolytic lesions in imaging features. Bone metastases most commonly occur in the pelvis, ribs, and vertebrae, and generally do not involve the skull and short bones of the hands and feet. Most patients with bone metastases have a history of primary tumor. Additionally, X-rays and CT of MM patients reveal 'rat-bite-like', perforated, honeycomb and speckled bone lesions, with the most typical being perforated punched-out appearance [6,7]. Conventionally, MM lesions on MRI are characterized by hypointensity in T1-weighted images and hyperintensity in T2-weighted images, with fat suppression in opposed-phase imaging and increased contrast enhancement in T1-weighted sequences [8]. The manifestations of this patient's CT and MRI favored MM, whereas, the results of other tests were inconsistent with MM. Therefore, based on the patient's clinical features and test results, tumor metastasis and MM can be excluded as potential diagnoses.

HPT can be classified into primary, secondary or tertiary. Osteosclerosis is more commonly associated with secondary than in primary HPT [9]. In patients with HPT, elevated PTH levels can affect and activate osteoclasts, consequently resulting in increased bone decalcification, lysis and resorption [1,10,11]. Patients with HPT commonly present with symptoms such as weakness, pathologic fractures, or bone pain, which can be misdiagnosed or oversight in the early stages of the disease. The imaging manifestations of bone disease in HPT are complex and diverse. The early-stages imaging of bone disease in of HPT reveals osteoporosis, presenting with widespread hypodensity, scanty bone trabeculae, a network-like appearance, and bone resorption and destruction [12,13]. In the disease progressive stage, subchondral bone resorption occurs, characterized by irregular edges, cortical depressions, or lacelike irregularity [12,13]. Diffuse osteoporosis, subchondral bone resorption, osteitis fibrosis cystica and salt-and-pepper appearance in the skull are typical manifestations of HPT [12,14]. Conventionally, many factors contribute to the development and progression of HPT, including hypocalcemia and decreased levels of 25(OH)D [11,15]. There fore, based on the combination of this patient's imaging and laboratory test results, the diagnosis of HPT with bone lesions was established. HPT with bone lesions can be challenging to distinguish from MM on imaging alone [16,17]. However, a comprehensive differentiation can be achieved by combining the result of bone marrow aspirate and biopsy, serum PTH levels, serum immunofixation electrophoresis, and clinical presentation.

6. Conclusion

To the best of our knowledge, bone disease in HPT exhibiting characteristic MM imaging manifestations is relatively rare. Due to the complexity and variety of imaging manifestations of bone disease in HPT, there are limitations in diagnosing the disease solely through imaging. Furthermore,

this suggests that clinicians should consider not only MM but also HPT with bone disease in patients with characteristic manifestations of MM on imaging. This also provides a new diagnostic idea for the clinic.

7. Author Contributions:

ZLY and YP was a major contributor to writing the manuscript, GBL was involved in the patient's clinical management, LSL performed imaging examination, LY contributed to the review of the manuscript and helped with language corrections. All authors read and approved the final version of the manuscript.

References

1. Rolighed L, Rejnmark L, Christiansen P. Bone involvement in primary hyperparathyroidism and changes after parathyroidectomy. *Eur Endocrinol* 2014;10:84-87.
2. Walker MD, Silverberg SJ. Primary hyperparathyroidism. *Nat Rev Endocrinol* 2018;14:115-125.
3. Press DM, Siperstein AE, Berber E, Shin JJ, Metzger R, Monteiro R, Mino J, Swagel W, Mitchell JC. The prevalence of undiagnosed and unrecognized primary hyperparathyroidism: A population-based analysis from the electronic medical record. *Surgery* 2013;154:1232-1237, 1237-1238.
4. Laurberg P, Andersen S, Bulow PI, Carle A. Hypothyroidism in the elderly: Pathophysiology, diagnosis and treatment. *Drugs Aging* 2005;22:23-38.
5. Faber J, Galloe AM. Changes in bone mass during prolonged subclinical hyperthyroidism due to L-thyroxine treatment: A meta-analysis. *Eur J Endocrinol* 1994;130:350-356.
6. Gorji J, Francis KC. Multiple myeloma. *Clin OrthopRelat Res* 1965;38:106-119.
7. Angtuaco EJ, Fassas AB, Walker R, Sethi R, Barlogie B. Multiple myeloma: Clinical review and diagnostic imaging. *Radiology* 2004;231:11-23.
8. Zamagni E, Tacchetti P, Cavo M. Imaging in multiple myeloma: How? When? *Blood* 2019;133:644-651.
9. Genant HK, Baron JM, Straus FH, Paloyan E, Jowsey J. Osteosclerosis in primary hyperparathyroidism. *Am J Med* 1975;59:104-113.
10. Lachungpa T, Sarawagi R, Chakkalakkooombil SV, Jayamohan AE. Imaging features of primary hyperparathyroidism. *BMJ Case Rep* 2014;2014
11. Michels TC, Kelly KM. Parathyroid disorders. *Am Fam Physician* 2013;88:249-257.
12. Bennett J, Suliburk JW, Moron FE. Osseous manifestations of primary hyperparathyroidism: Imaging findings. *Int J Endocrinol* 2020;2020:3146535.
13. Chang CY, Rosenthal DI, Mitchell DM, Handa A, Kattapuram SV, Huang AJ. Imaging findings of metabolic bone disease. *Radiographics* 2016;36:1871-1887.
14. Bandeira F, Cusano NE, Silva BC, Cassibba S, Almeida CB, Machado

Annals of Clinical and Medical Case Reports

- VC, Bilezikian JP. Bone disease in primary hyperparathyroidism. *Arq Bras Endocrinol Metabol* 2014;58:553-561.
15. Rodriguez-Ortiz ME, Rodriguez M. Recent advances in understanding and managing secondary hyperparathyroidism in chronic kidney disease. *F1000Res* 2020;9
16. Liu H, Luo K, Liao S, Tang H, Mo J, Xie T, Li C, Li B, Liu Y, Zhan X. Diagnosis and treatment of primary hyperparathyroidism with pathological fracture of the limbs: A retrospective observational study. *Medicine (Baltimore)* 2022;101:e29966.
17. Enell J, Bayadsi H, Lundgren E, Hennings J. Primary hyperparathyroidism is underdiagnosed and suboptimally treated in the clinical setting. *World J Surg* 2018;42:2825-2834.